



*...Fun last lab for me!  
How happy I am to see!!*

## ***BI 358 Discussion 11: Vision Lab w/Eye Dissections***

***I. Announcements*** Final papers due next Tuesday, March 17<sup>th</sup>, in Pat's box, 77 Klamath < 5 pm. Q?

### ***II. Anatomy & Physiology of the Eye***

LN Dierks & RE Hammond, Carolina Biological 1980

CC Francis & AH Martin 1975

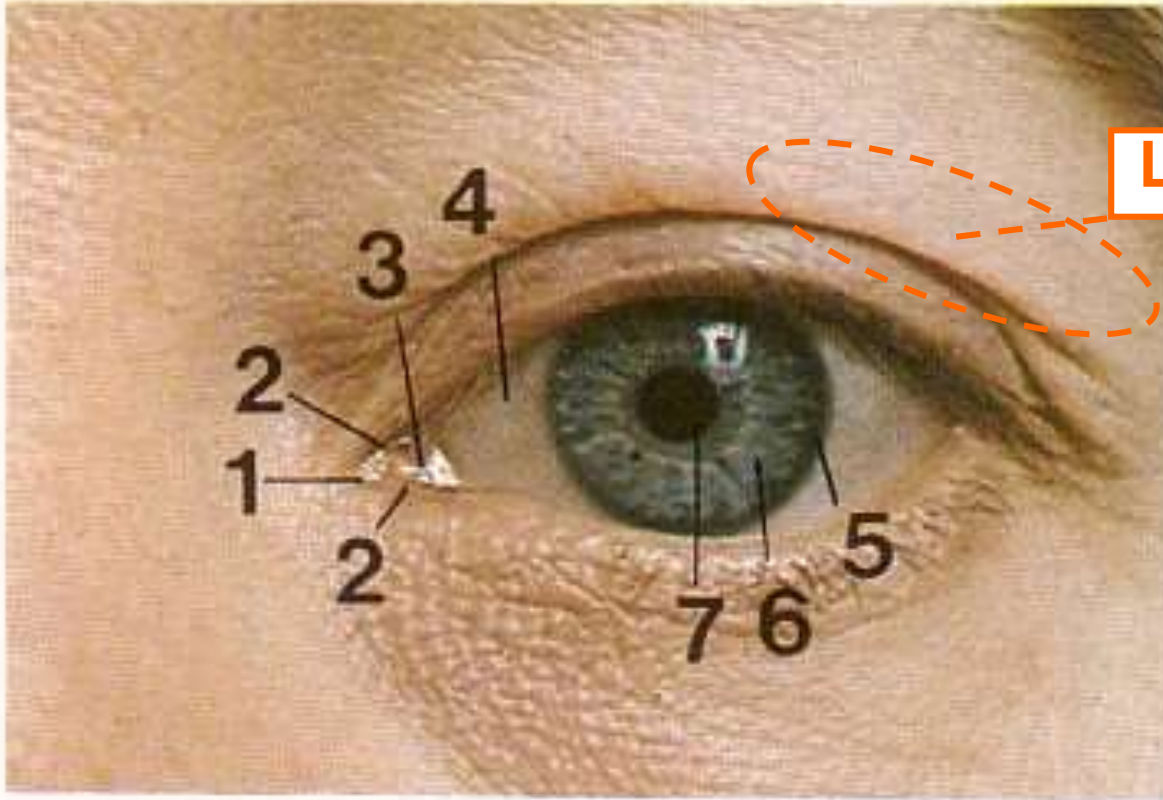
RMH McMinn & RT Hutchings 1977

DA Morton, KD Peterson & KH Albertine 2007

LS Sherwood 2006

### ***III. Lab Tests + Eye Dissections***

# Eye (L) Surface Anatomy



**A**

**Lacrimal gland!**

## **A Left eye**

- 1 Lacrimal caruncle
- 2 Lacrimal papilla
- 3 Plica semilunaris
- 4 Sclera
- 5 Limbus (corneoscleral junction)
- 6 Iris
- 7 Pupil

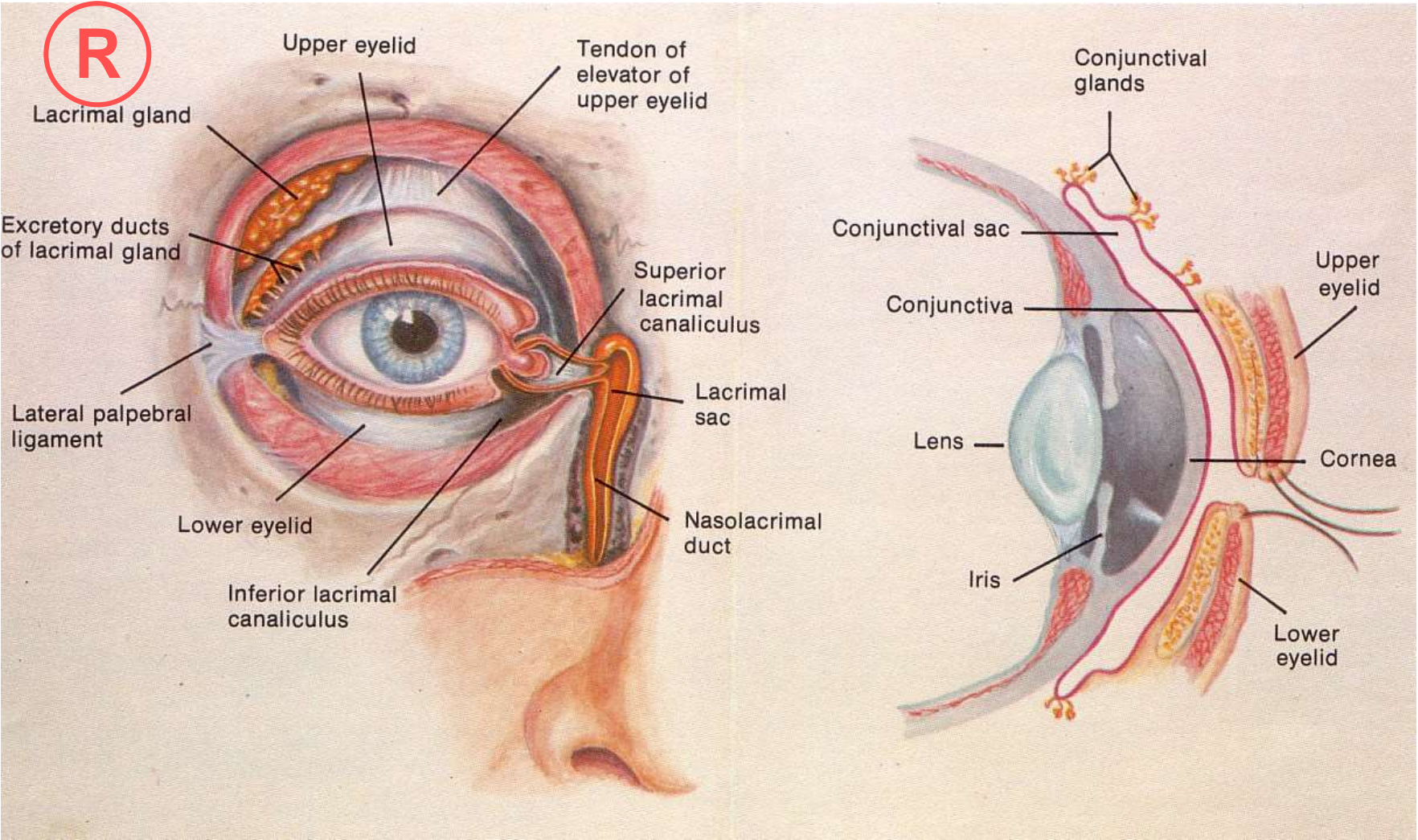
Caruncle = L. wart

Papilla = L. nipple

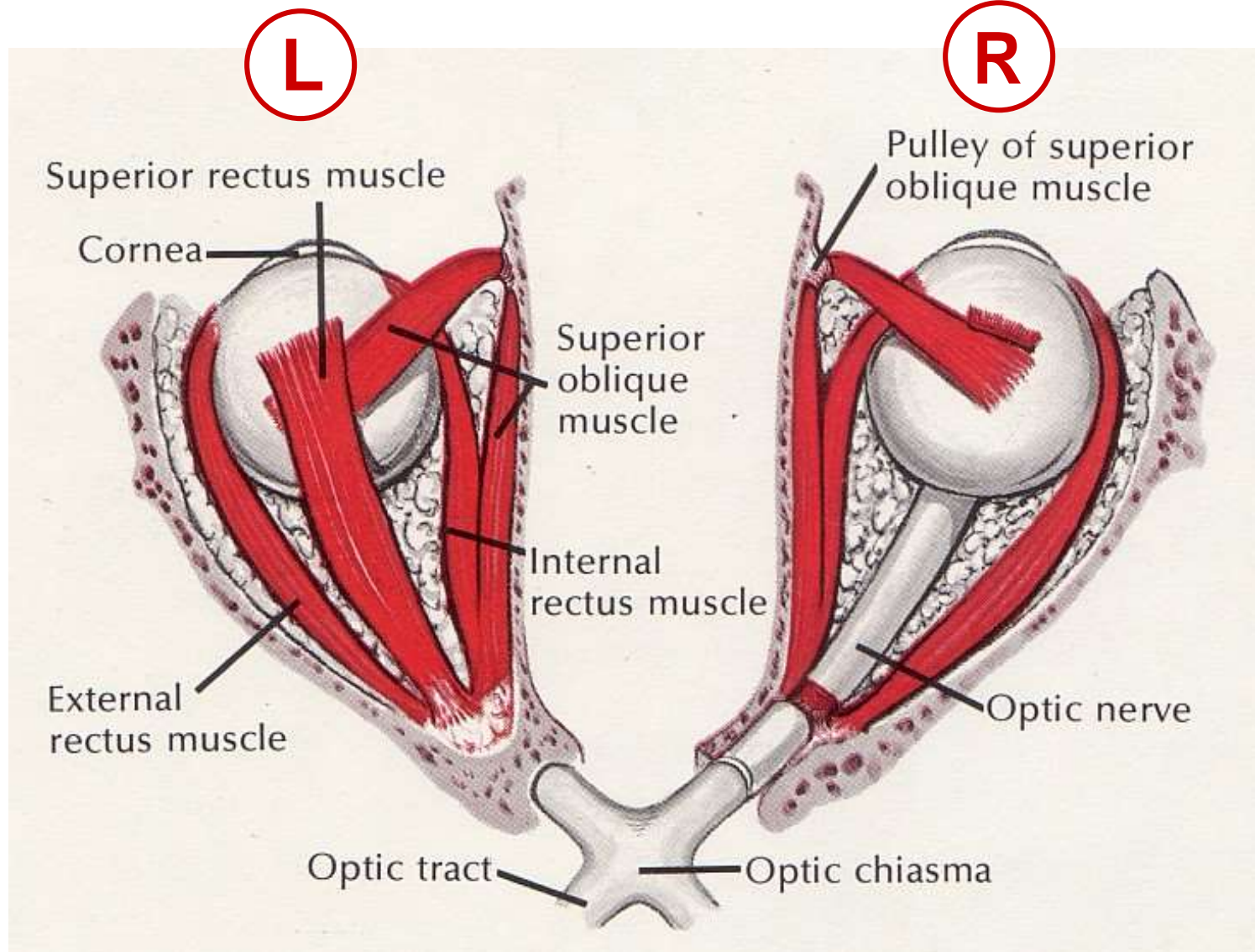
Sclera = L. hard/white

Limbus = L. margin/border

# Eye Drops Out Nose? Why?

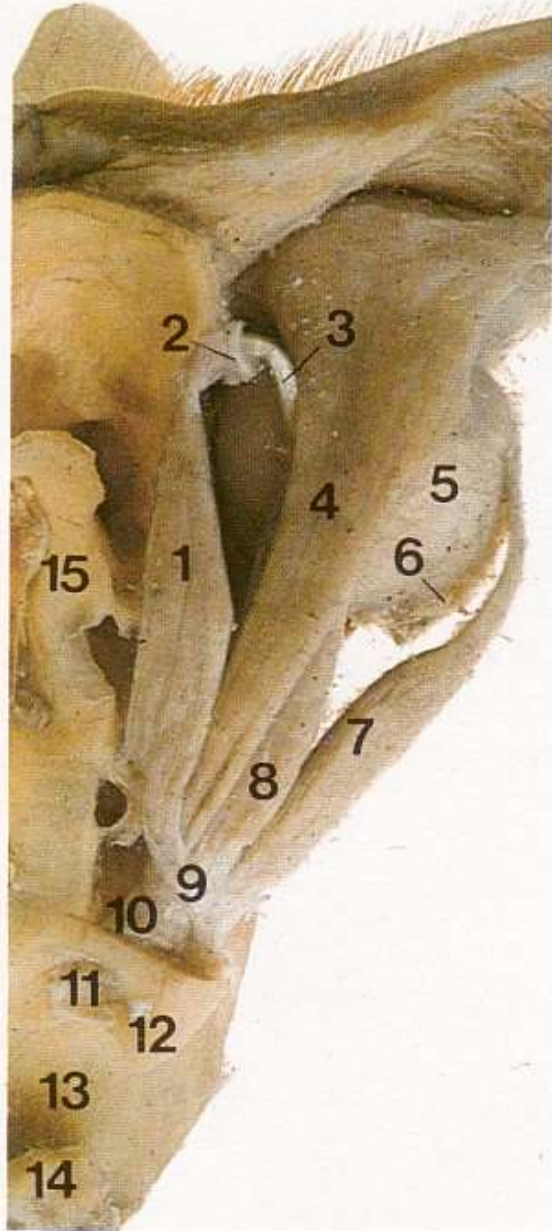

# Eye Muscles Superior View



# Eye (R) Superior View Dissection

B

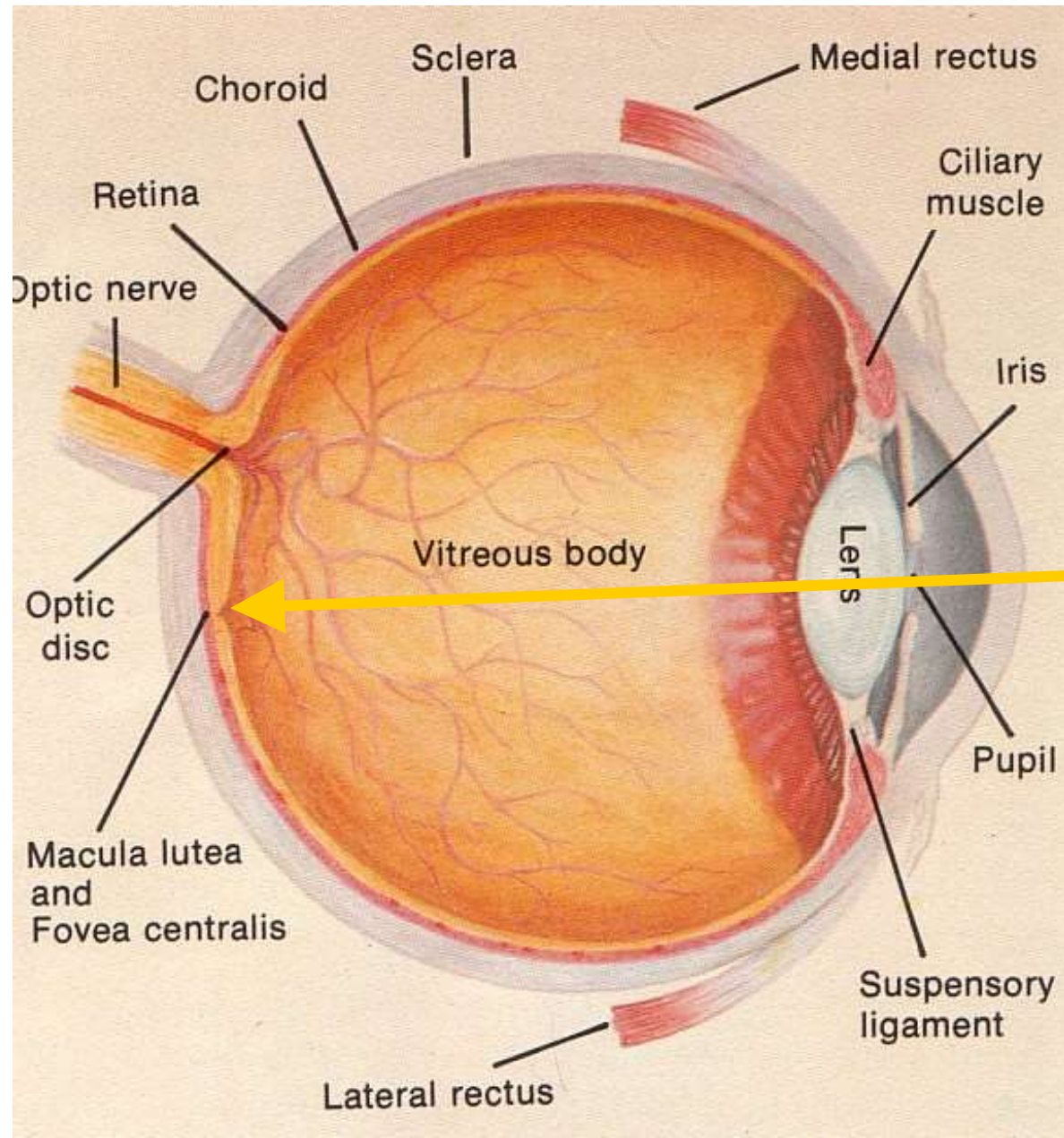


- 1 Superior oblique — Gr. pulley!
- 2 Trochlea ←
- 3 Tendon of superior oblique
- 4 Levator palpebrae superioris
- 5 Eyeball
- 6 Inferior oblique
- 7 Lateral rectus
- 8 Superior rectus
- 9 Tendinous ring
- 10 Optic nerve
- 11 Optic canal
- 12 Anterior clinoid process
- 13 Sella turcica (pituitary fossa)
- 14 Posterior clinoid process
- 15 Ethmoidal air cells
- 16 Inferior rectus

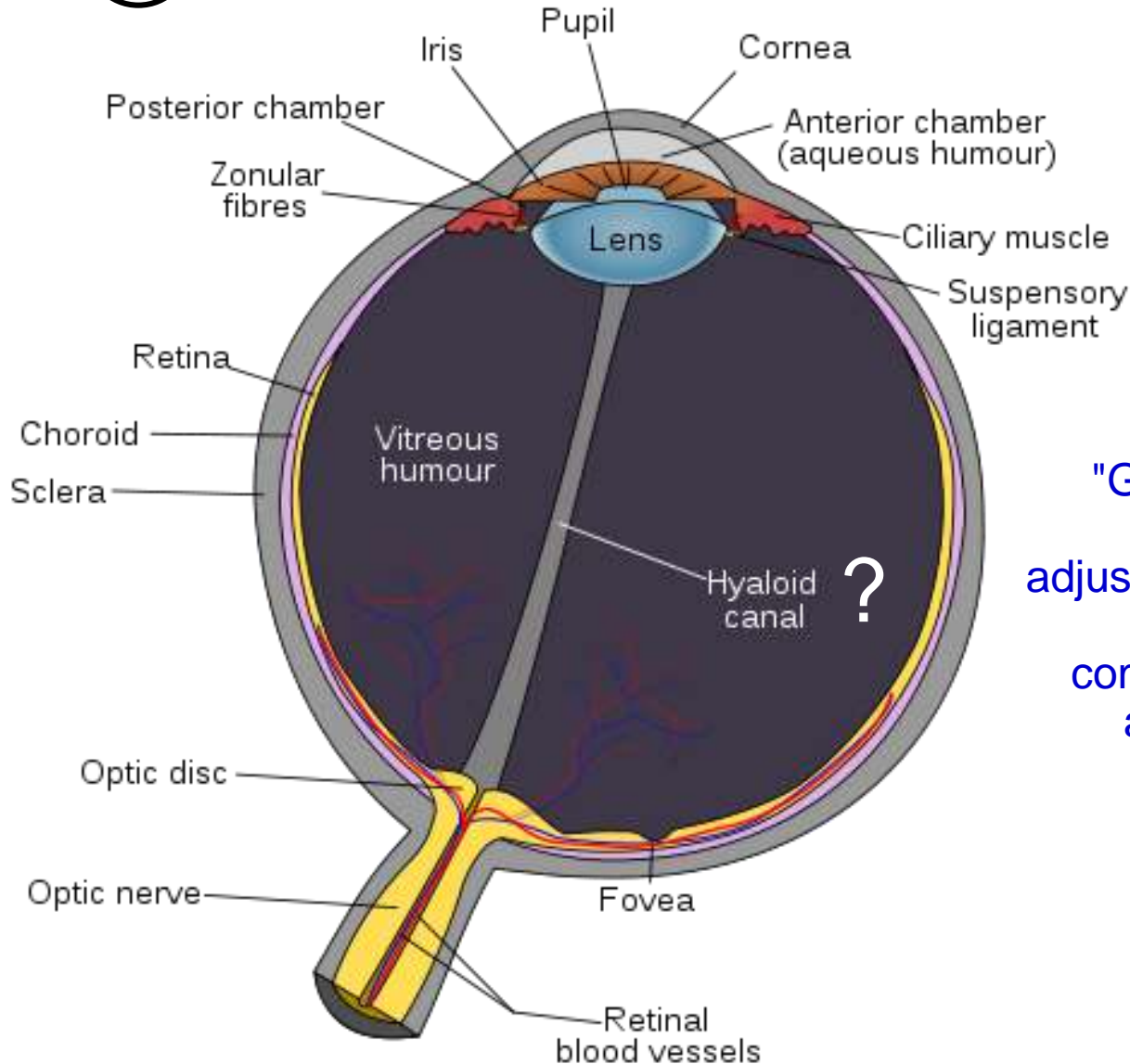
# Eye (R) Superior View

Posterior

Anterior



# Eye (R) Superior View Horizontal Dissection



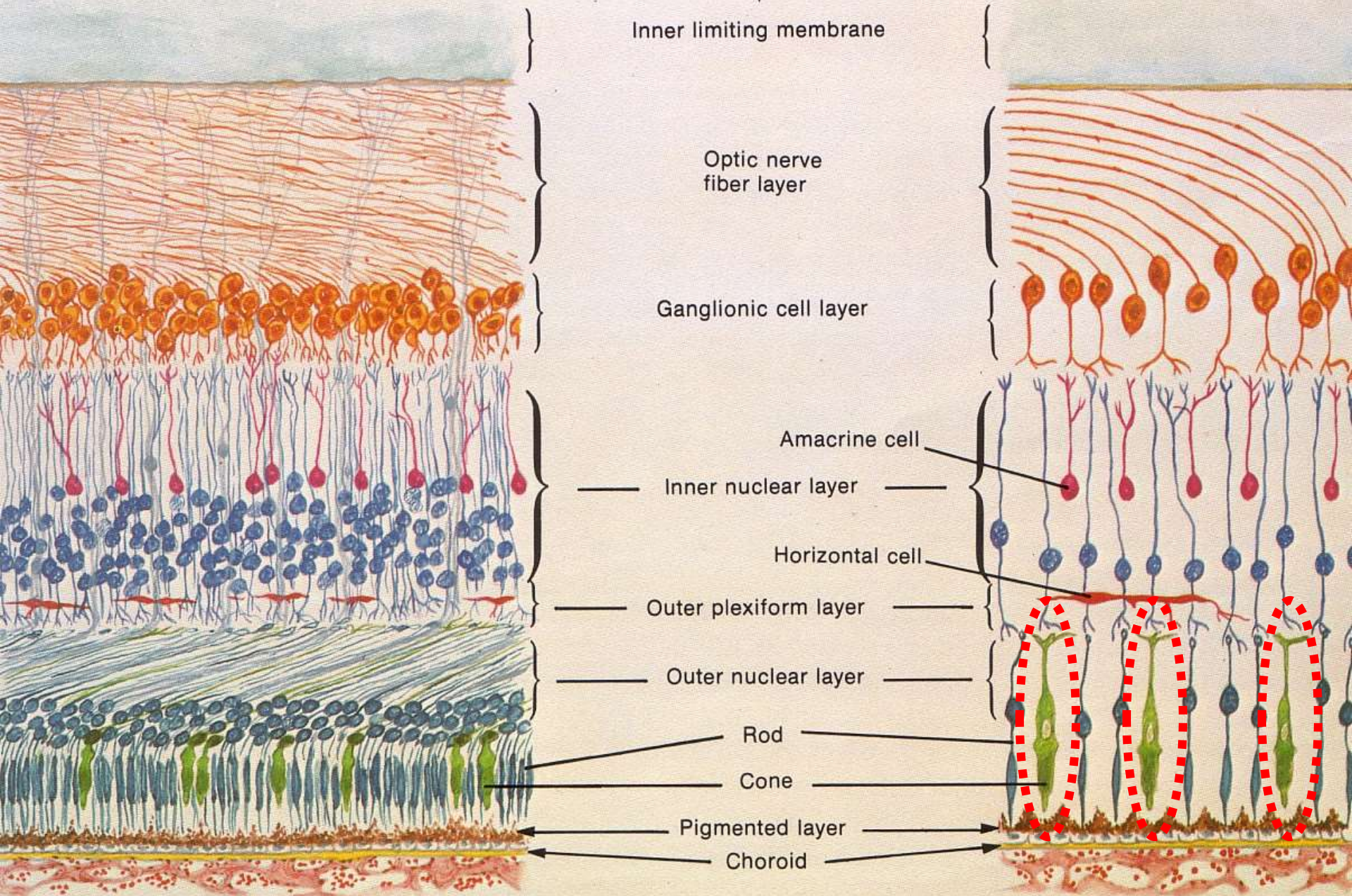
"Glass-like" canal:  
Fetal remnant &  
adjustable reservoir of  
mobile liquid to  
compensate during  
accommodation!

TPA Stuart, *Journal of Physiology*, Mar 29, 1904!

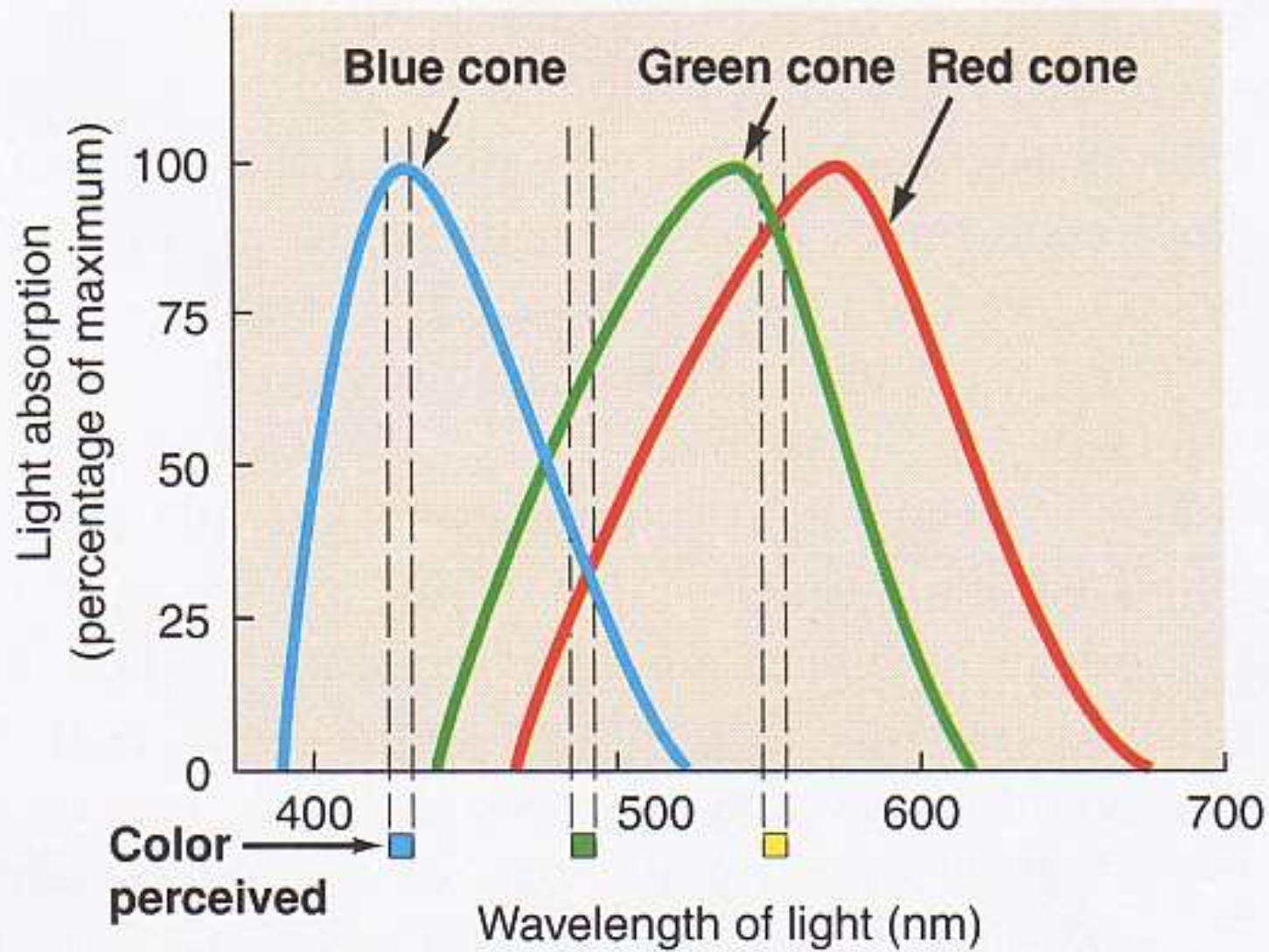
<http://www.ncbi.nlm.nih.gov/pmc/articles/PMC1465472/?tool=pmcentrez>

# Retinal Layers

Light



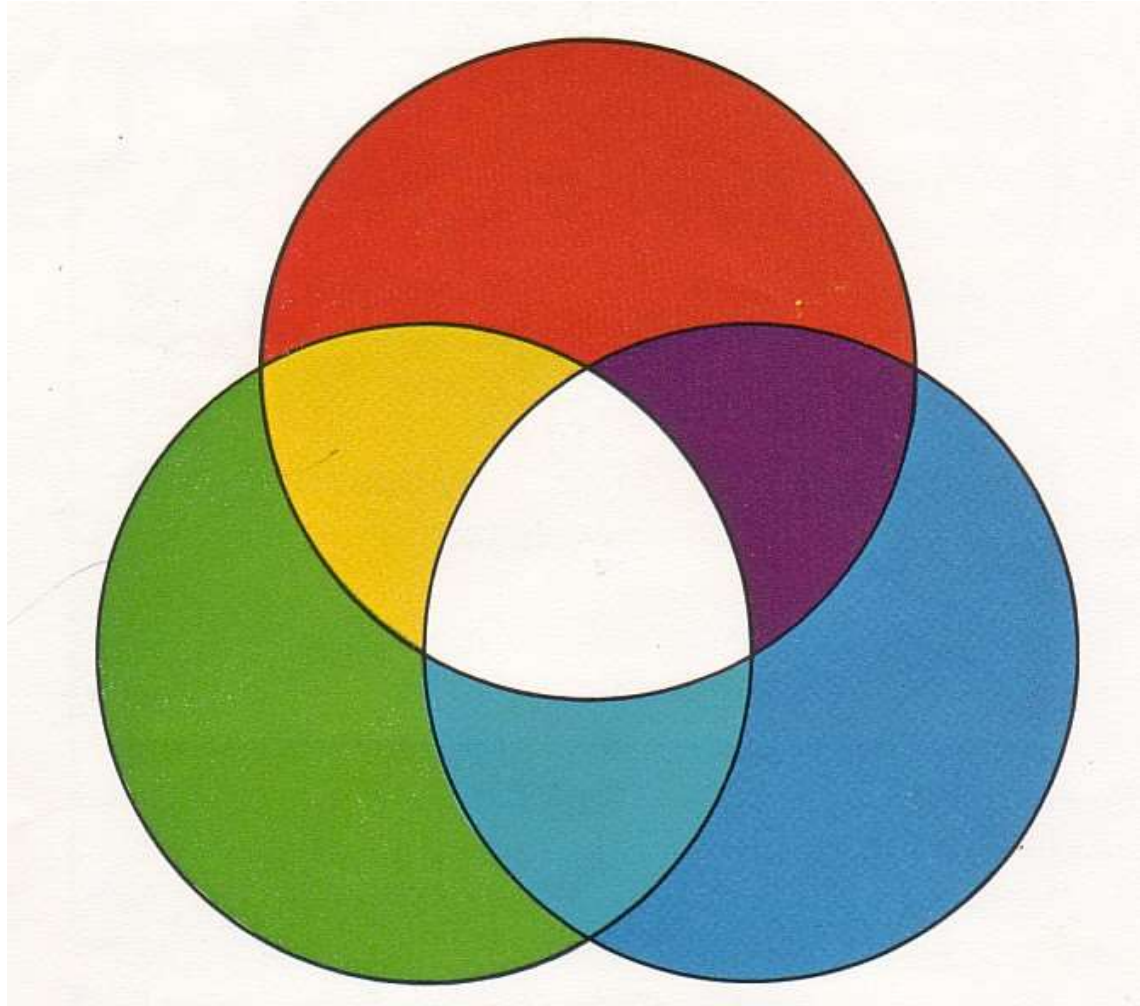





Visible spectrum



***Intermediate Colors Are Produced  
When 1<sup>o</sup> Colors Are Superimposed***

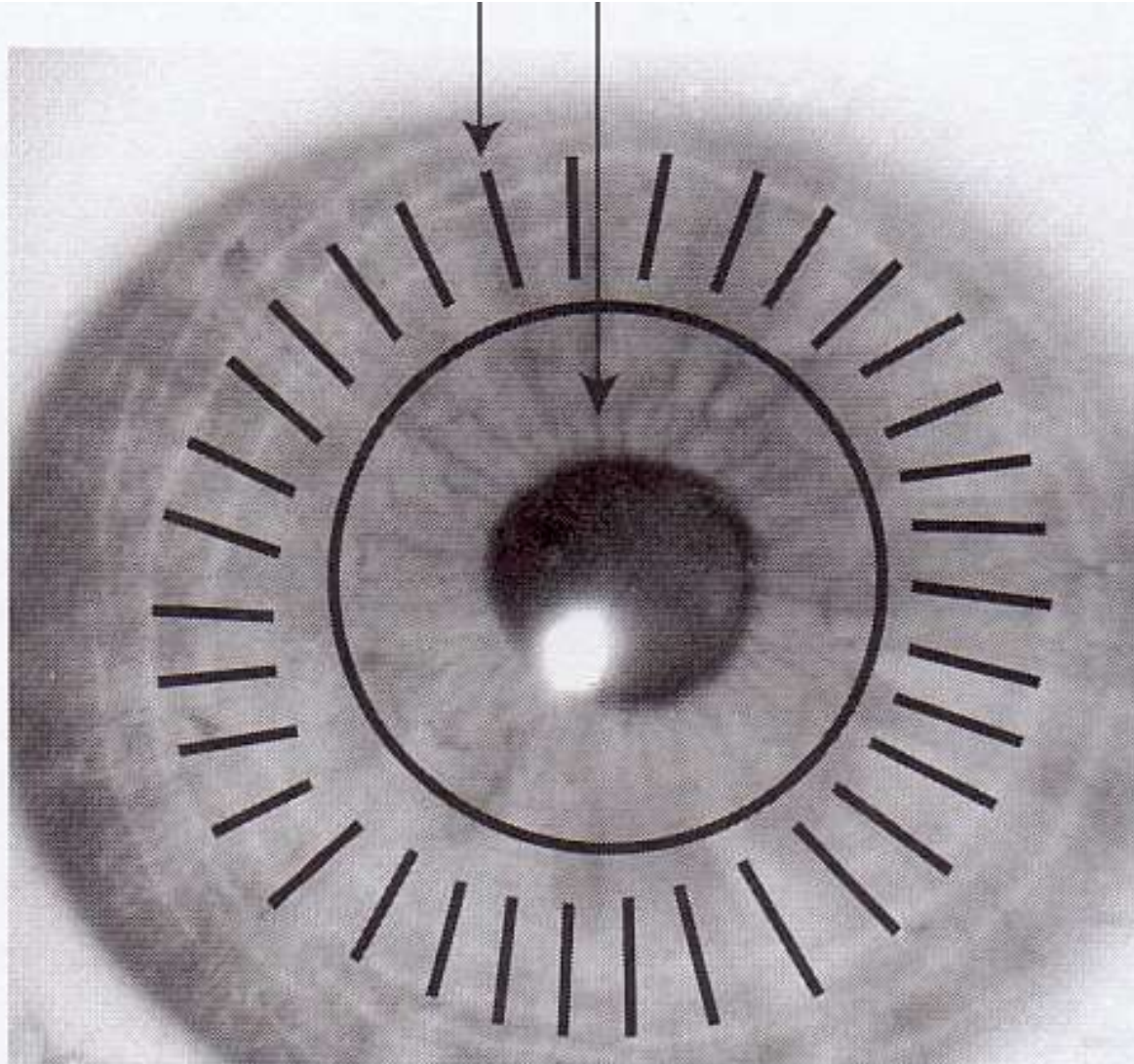






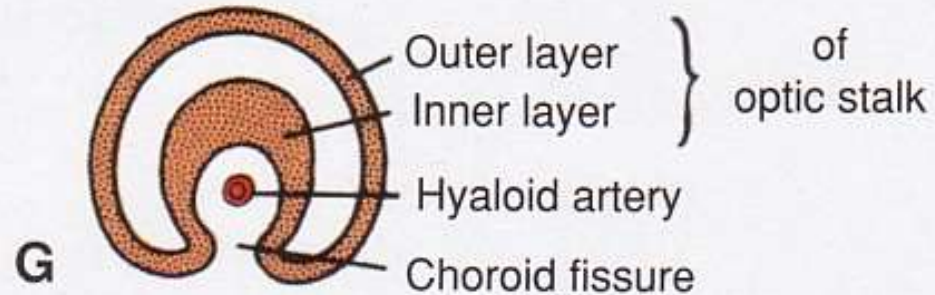
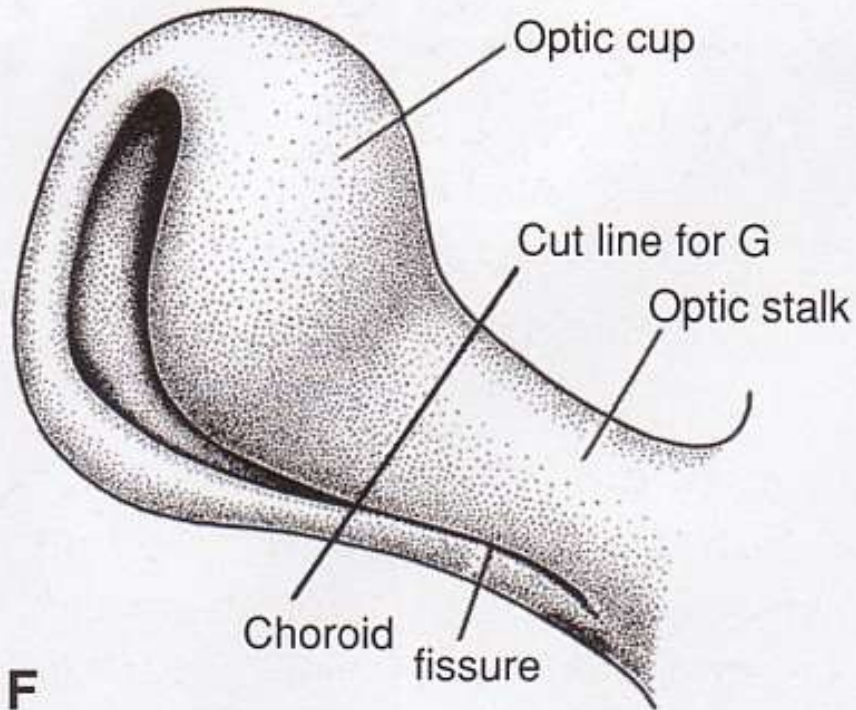
# *Smooth Muscles of the Iris*

**Dilator    Sphincter**



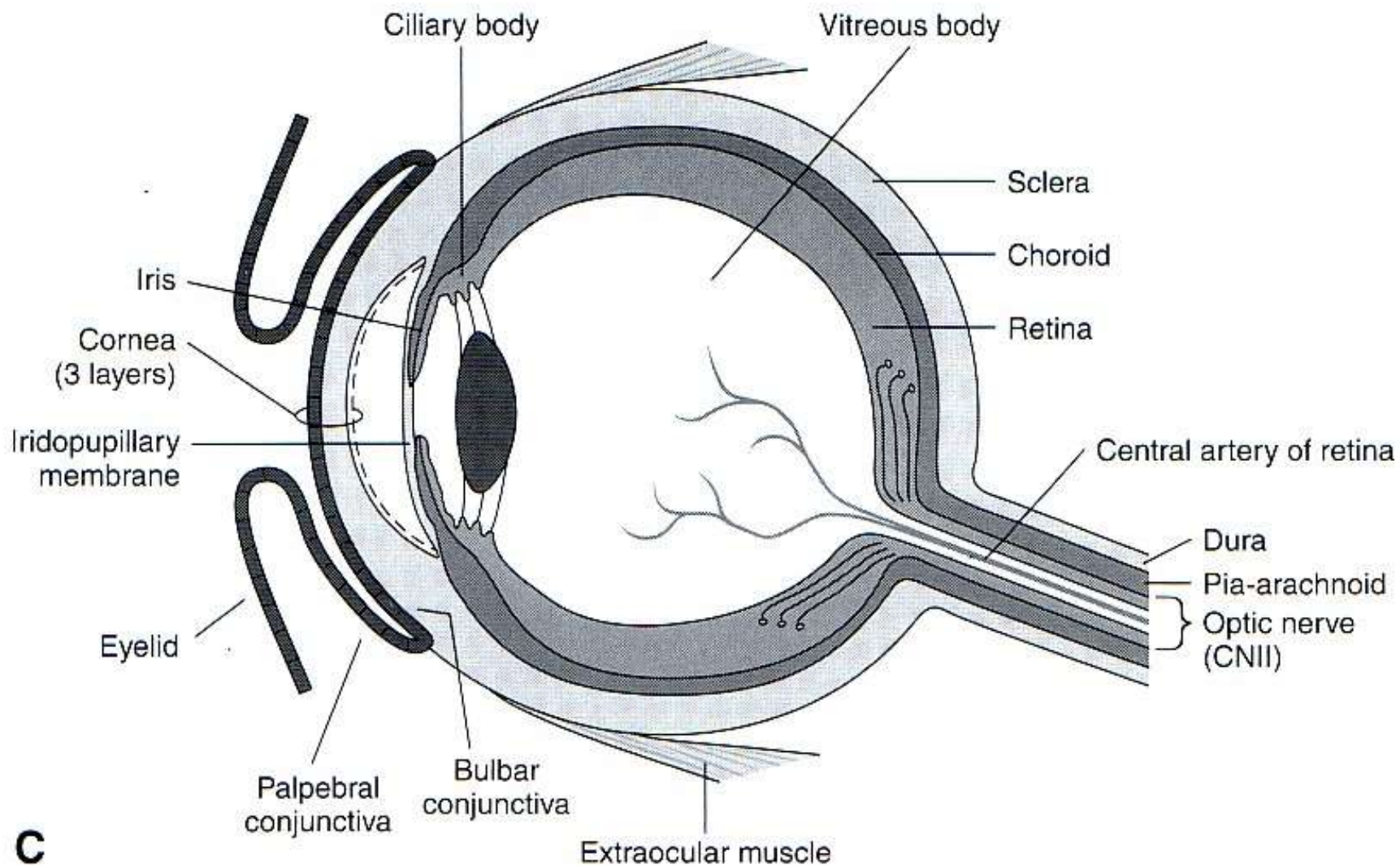
**C**

# ***The Optic Cup & Optic Stalk are Evaginations of the Diencephalon***

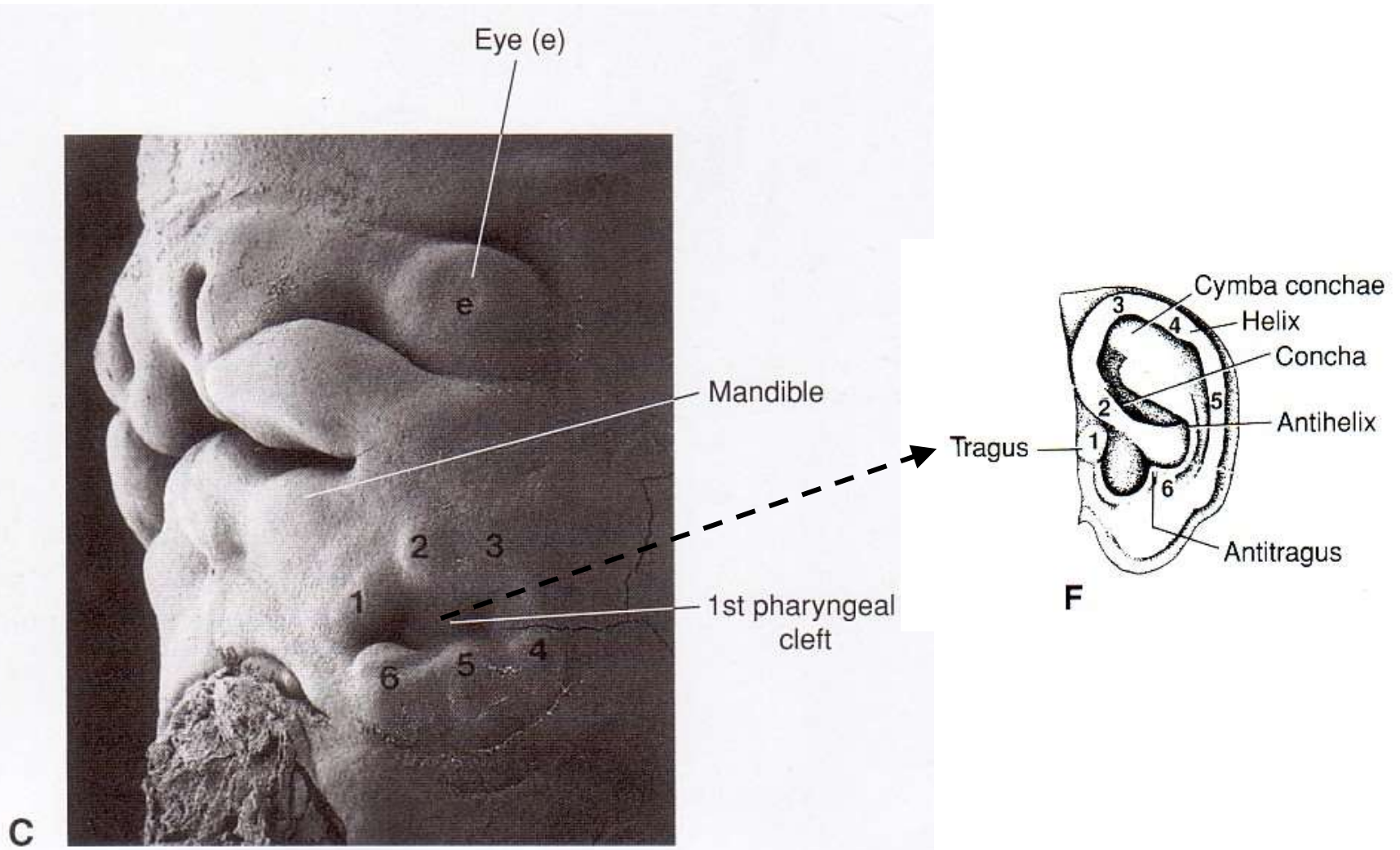


***“The Eye Backs Out of the Brain”***

# *Conjunctiva folds back on itself!*

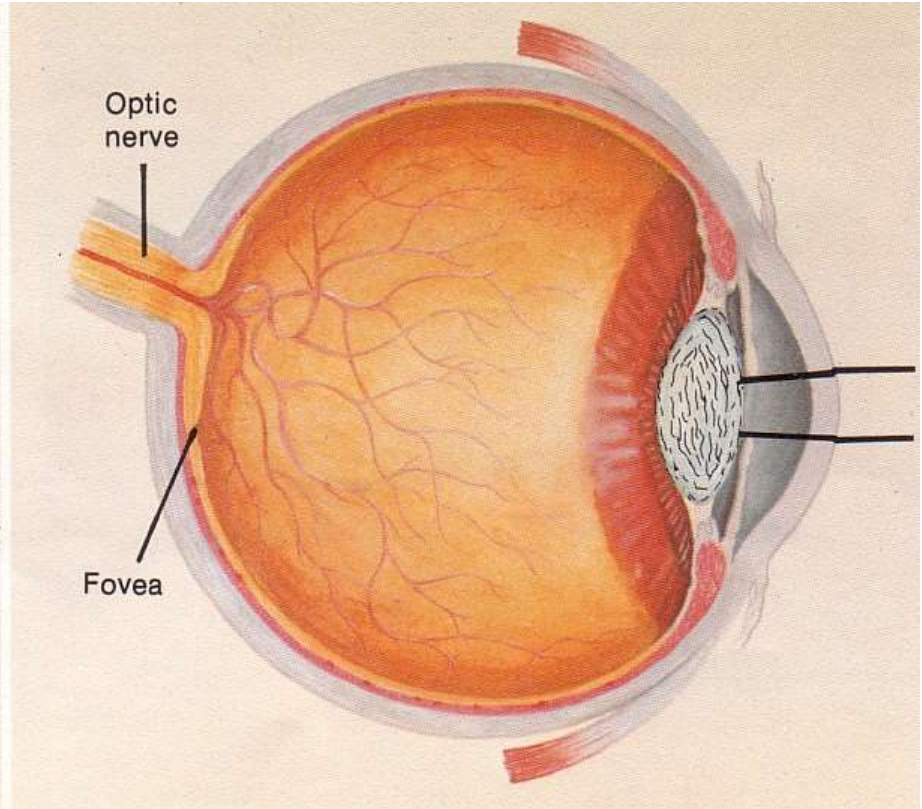
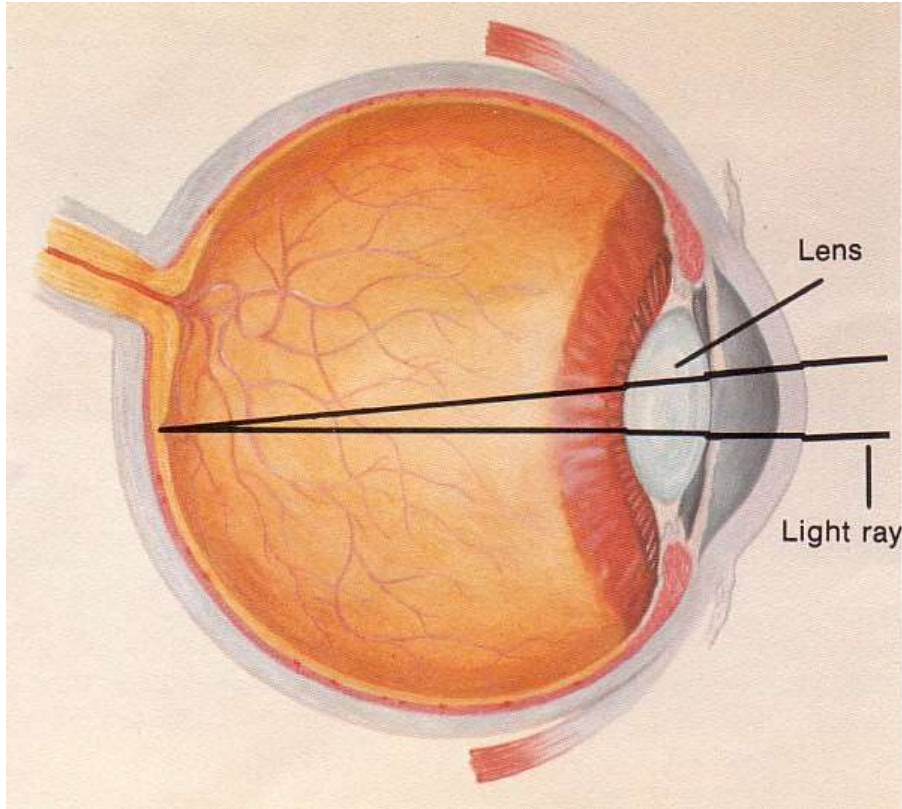


# Eye & External Ear Formation

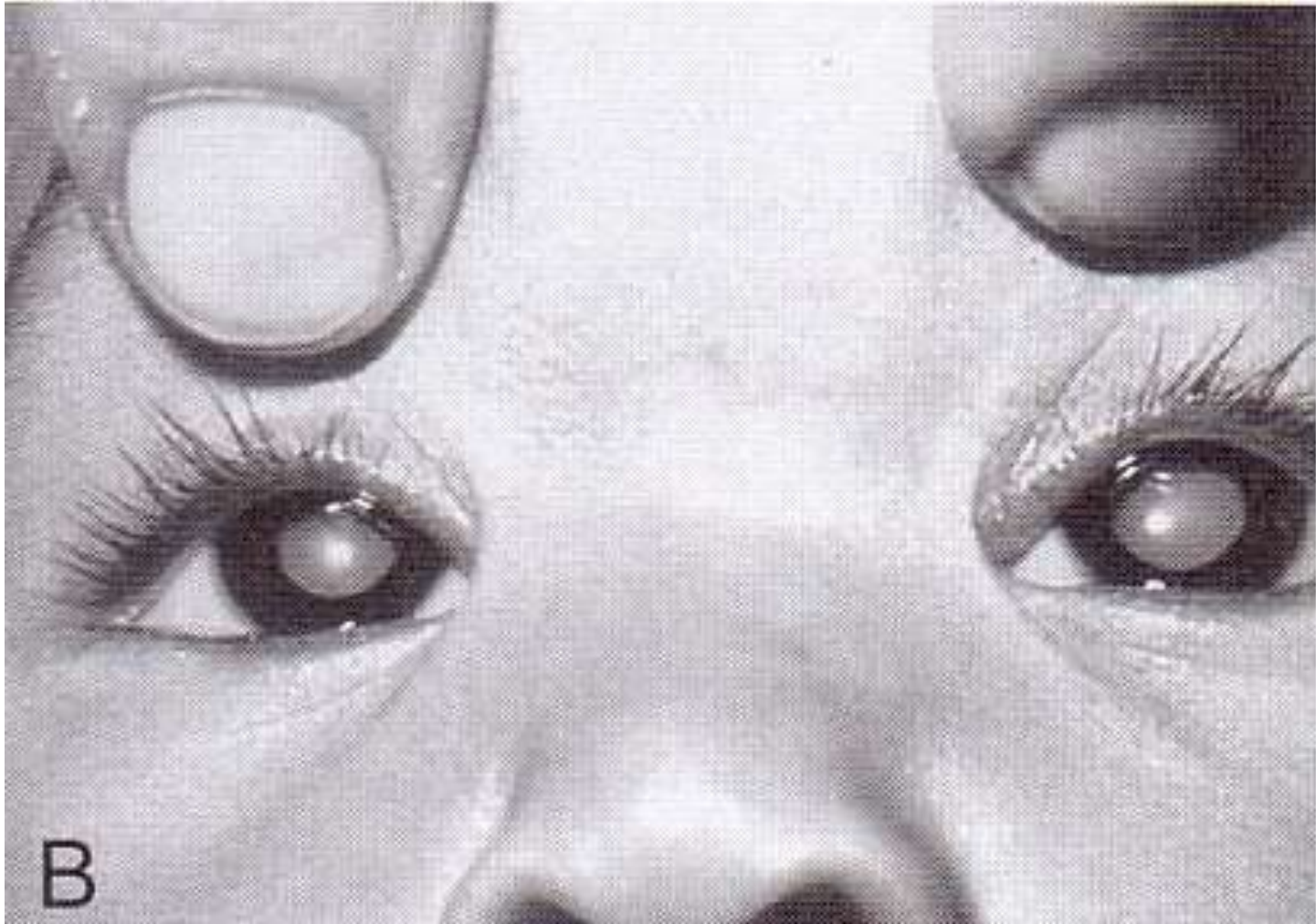



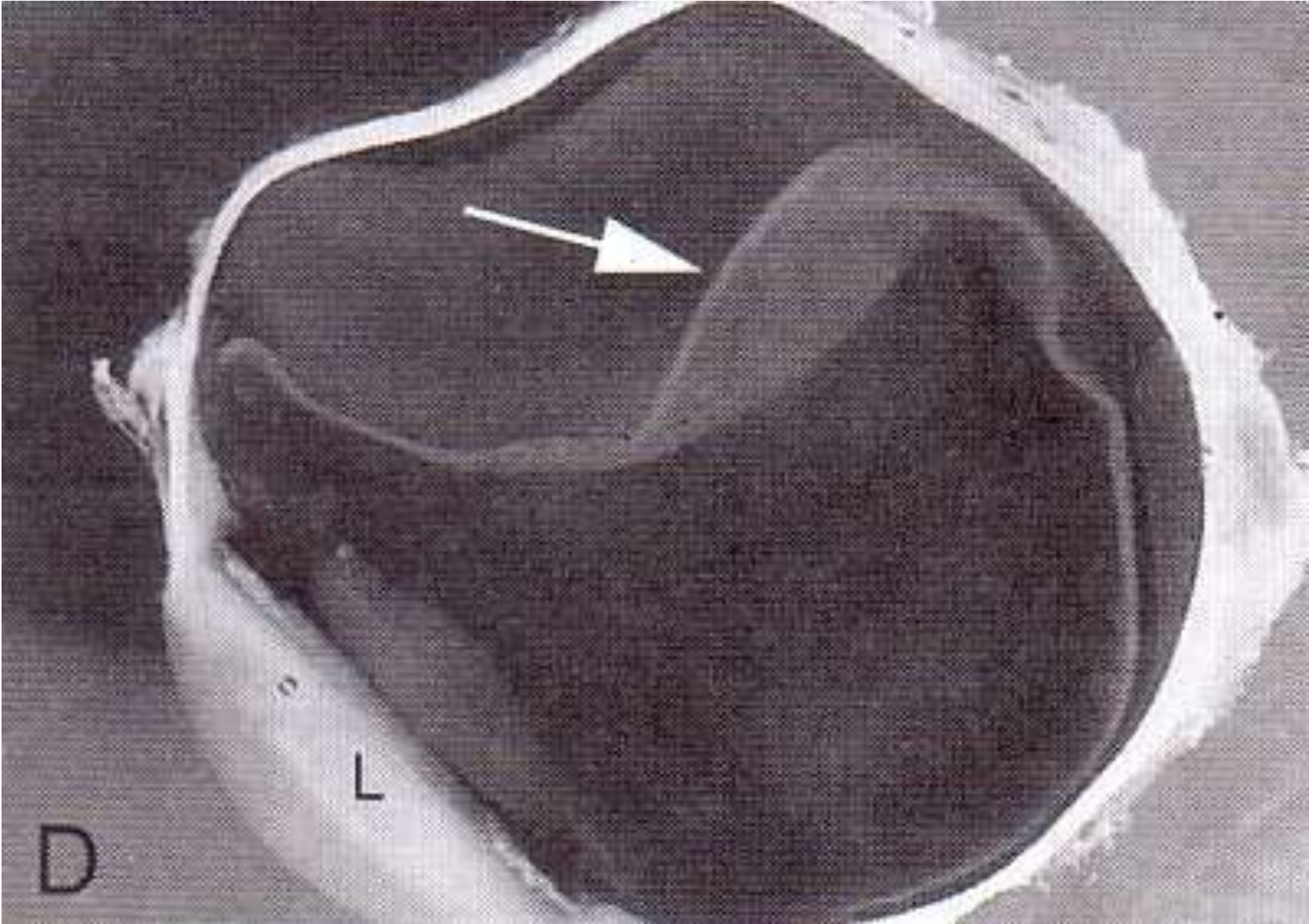
# *Normal vs. Cataract Lens*



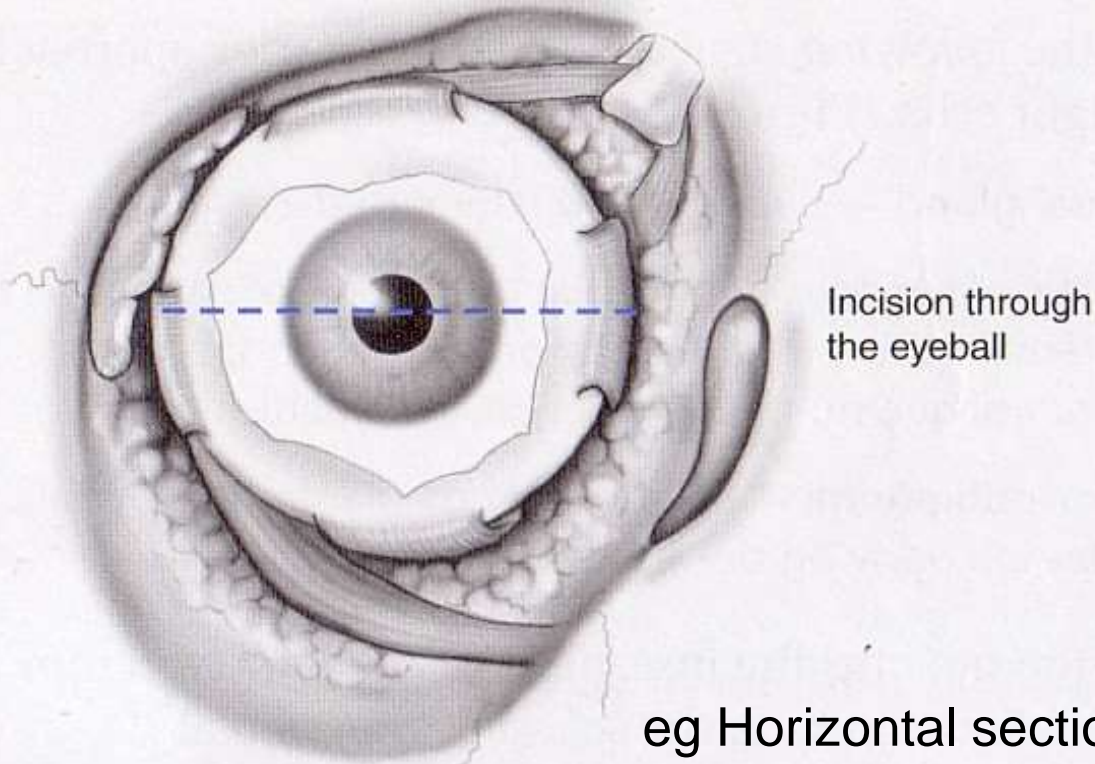
# *Cataracts in Child*



# ***Detached Retina***



# Lab Eye Tests + Dissection Overview



Incision through  
the eyeball

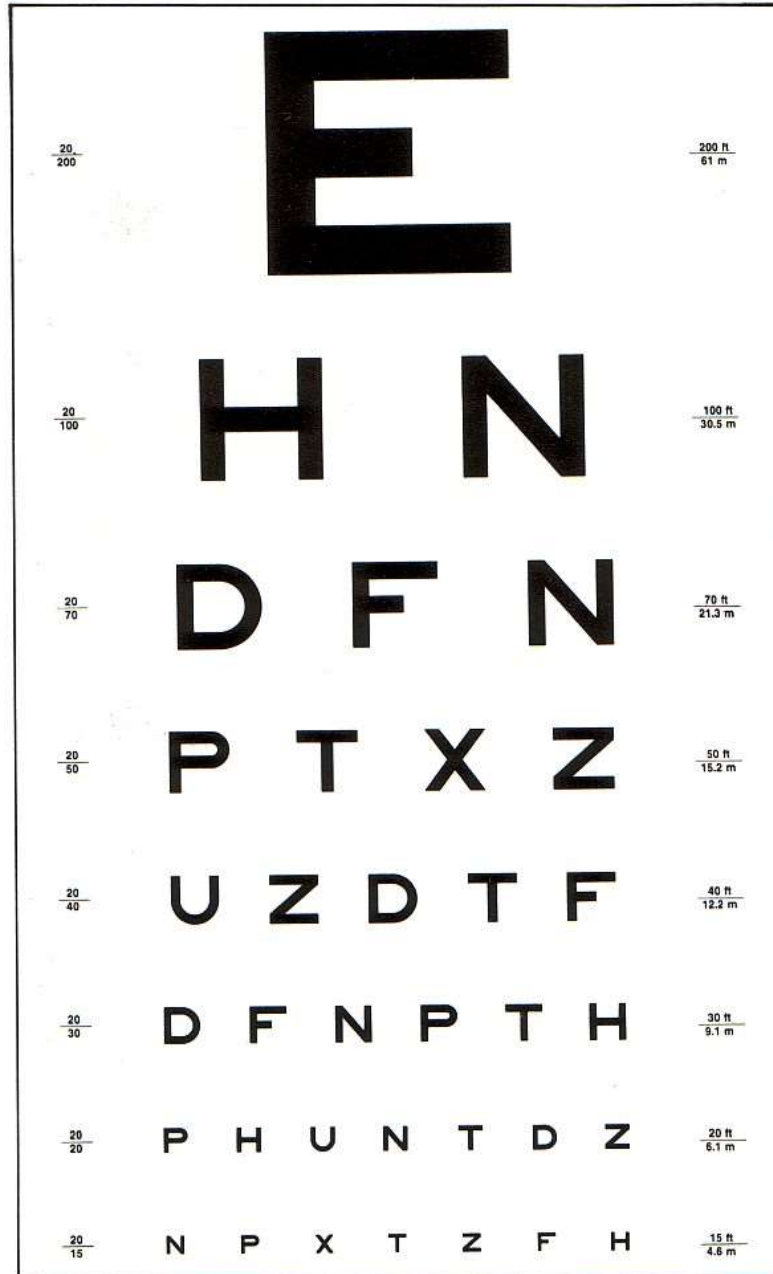
eg Horizontal section,  
see fig p 11-2

- ① Eye Dominance
- ② Snellen Acuity
- ③ Astigmatism
- ④ Blind Spot Mapping
- ⑤ Dissection of Cow & Pig Eyes  
See pp 11-1, 11-2

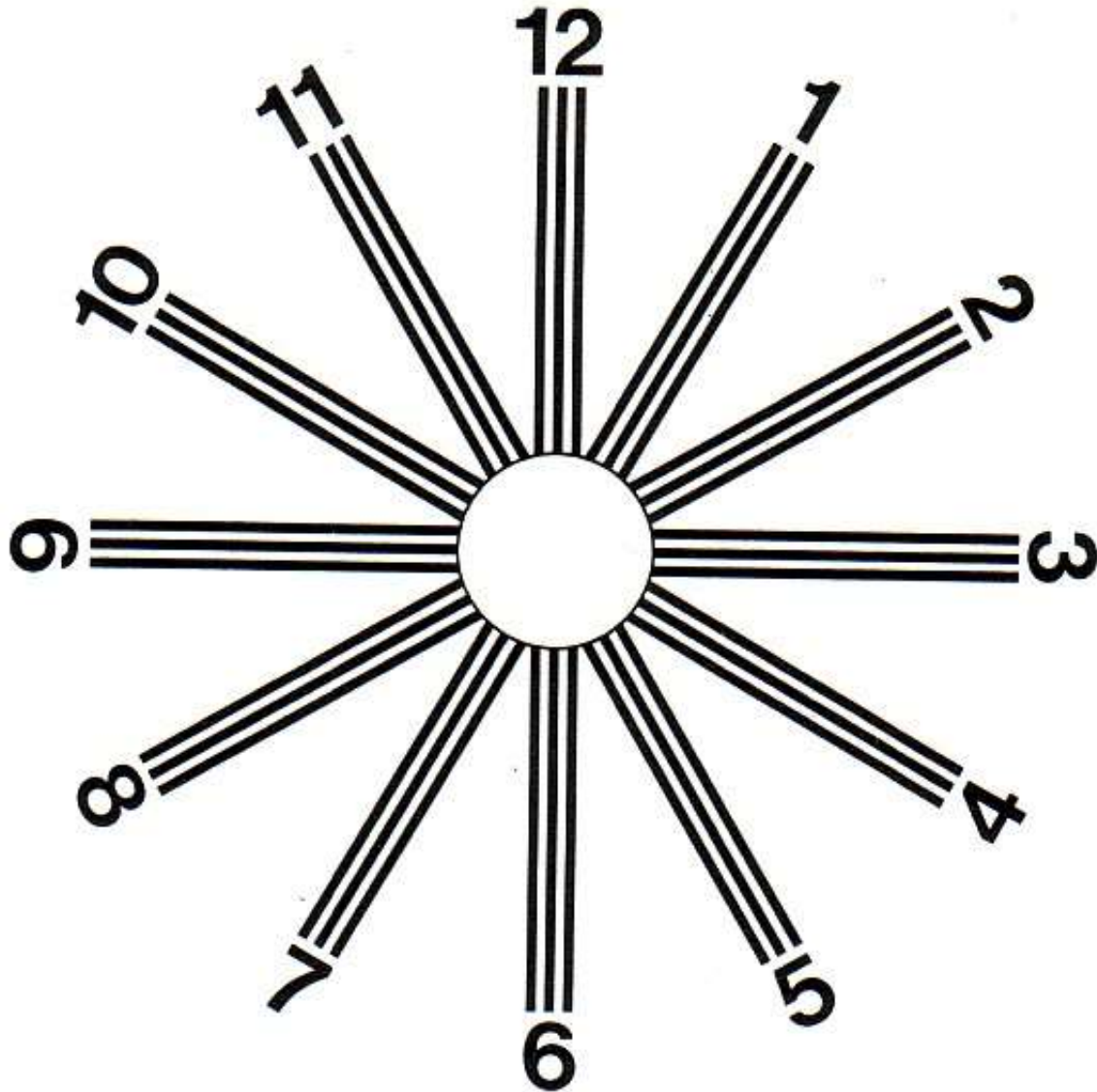
# *Eye Dominance?*



# Snellen Visual Acuity Test

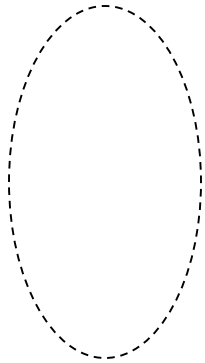


# Astigmatism Test



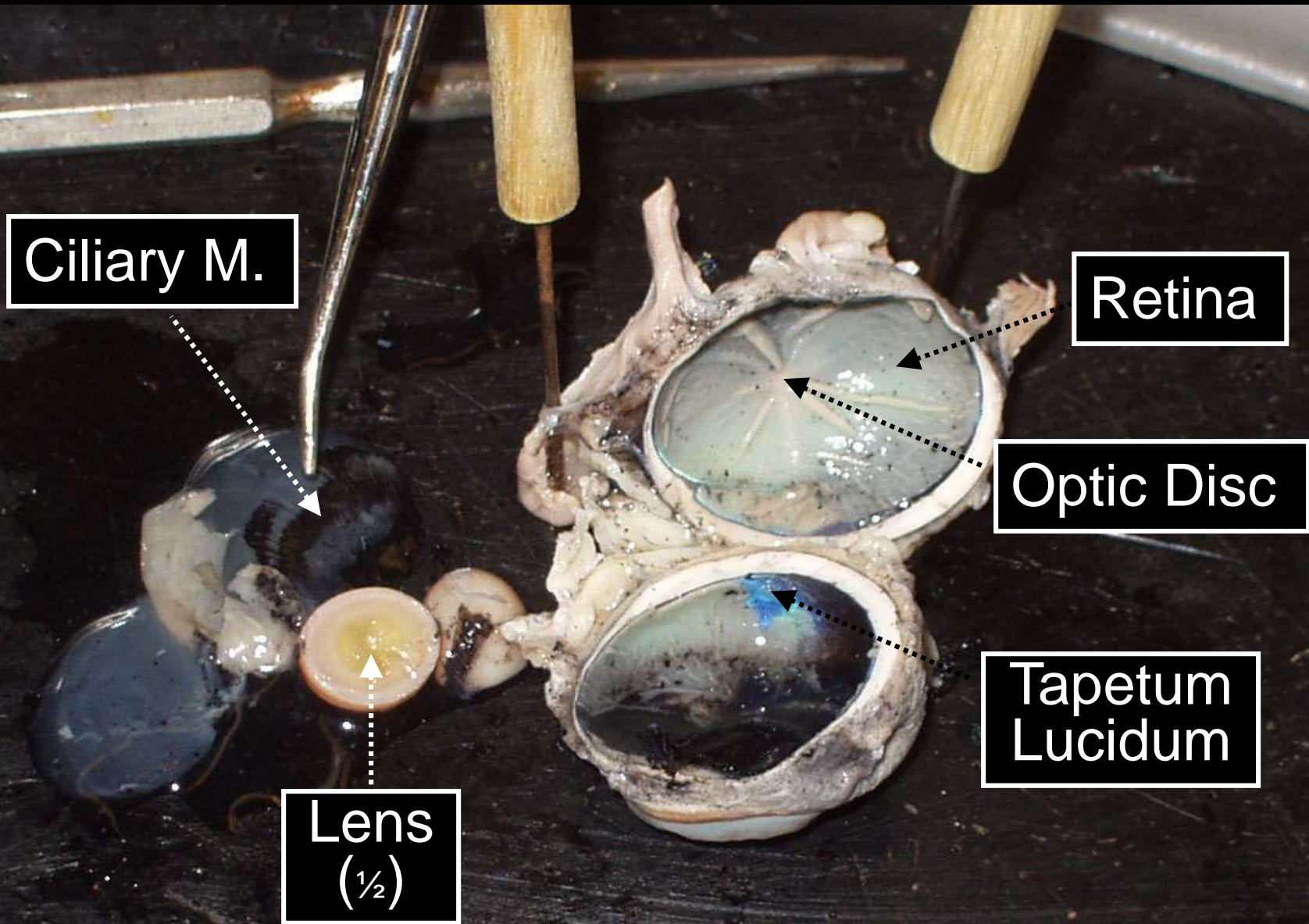
# ***Blind Spot Mapping?***

# 2





# *Jennifer Finley's Eye Dissection!*



*Tapetum Lucidum* "Bright Tapestry"  
Illuminated Due to Flash Photography

