



...Update on personal topic + outlines!

BI 199 APWT Discussion 8

- I. Announcements **Topic + thematic poster outline update.** If you haven't done so send .doc/.docx file by e-mail attachment to:
lombardi@uoregon.edu Q?
- II. Exploring Upper Extremity Bones from the Anatomy Lab
- III. Q? + Open Discussion

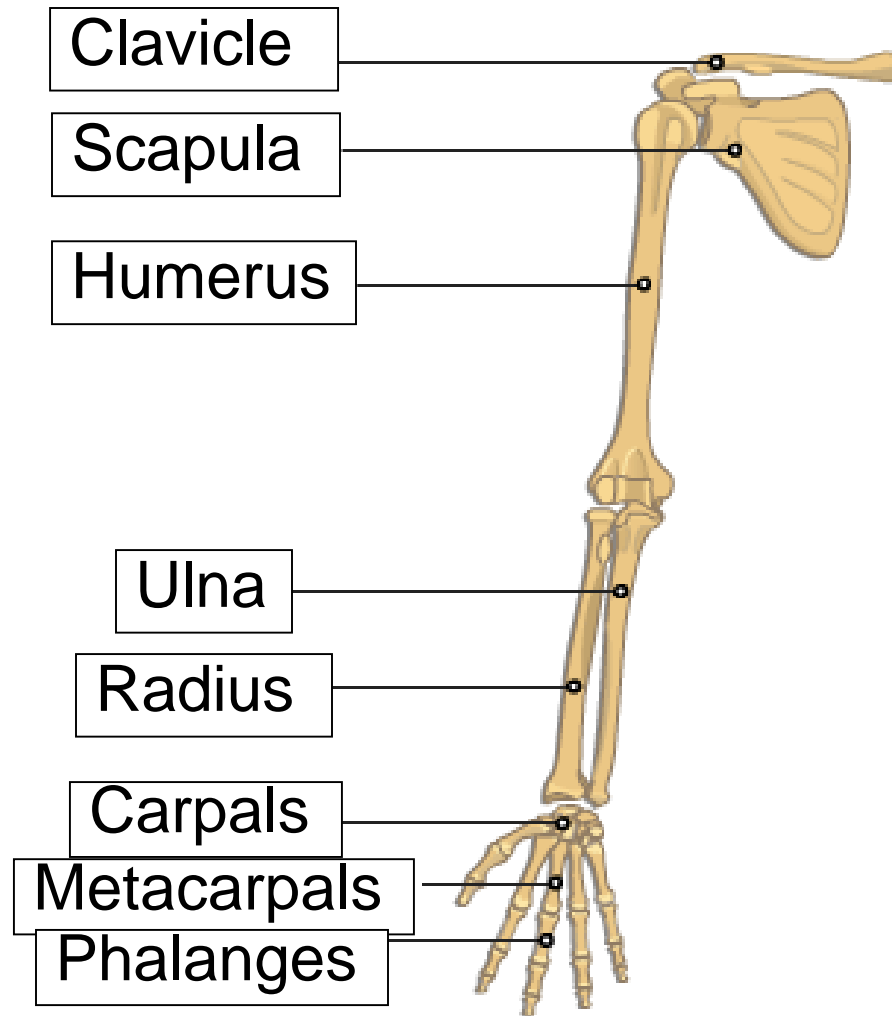
Upper Extremity Exploration 1

Working with members of your group, identify & arrange in correct anatomical orientation these bones:

1. Scapula
2. Clavicle
3. Humerus
4. Radius
5. Ulna
6. Carpals
7. Metacarpals & Phalanges

What are the *nicknames* or *lay terms* for 1-7 above?
One member should take notes and summarize groups members' comments.

Upper Extremity Bones



Upper Extremity Exploration 2

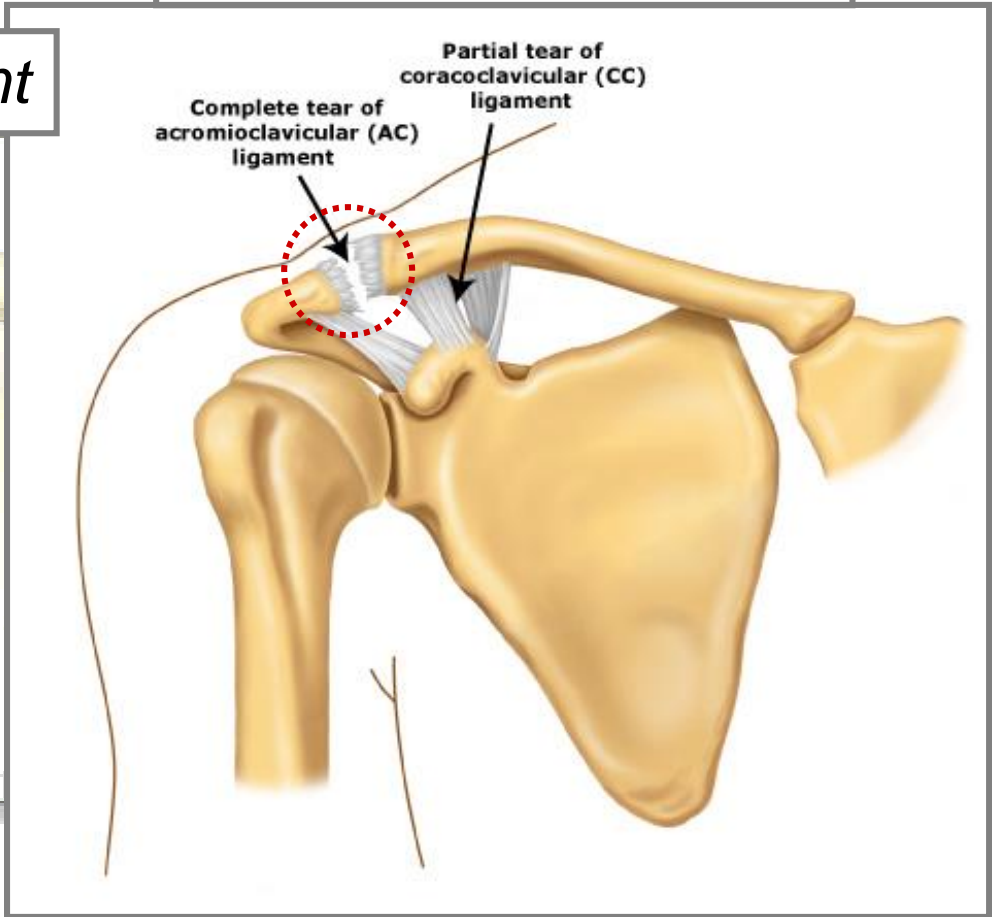
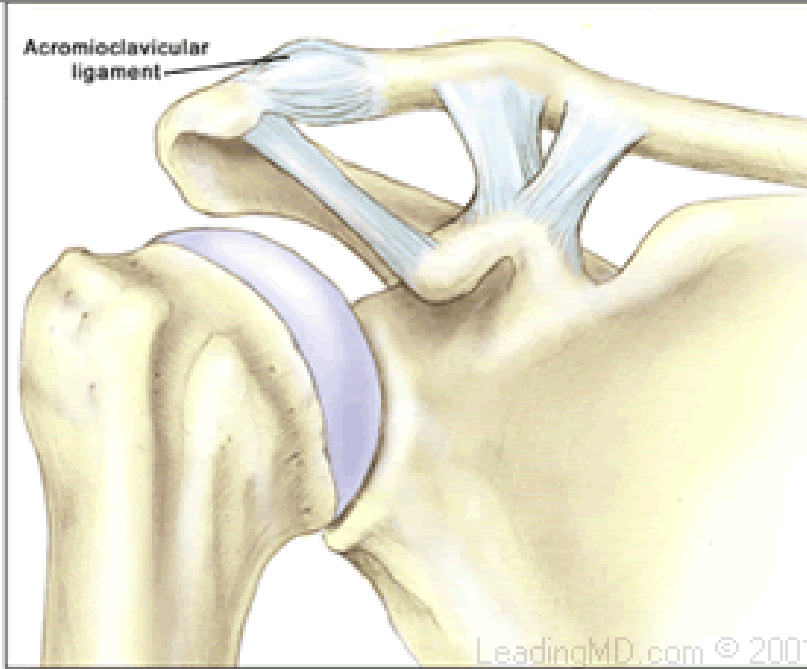
Identify the following joints & segments:

1. Acromion-Clavicular
2. Sterno-Clavicular
3. Shoulder
4. Elbow
5. Wrist
6. Metacarpal-Phalangeal
7. Proximal, mid- & distal phalanges

For # 1 & 2 use a piece of yellow tape to indicate ligaments. How might *separations* of 1. and 2. occur? What *kinds of forces* might be involved?

Acromioclavicular Tear

Normal Acromioclavicular Joint



AC Separation: X-ray & Combined Surface Anatomy

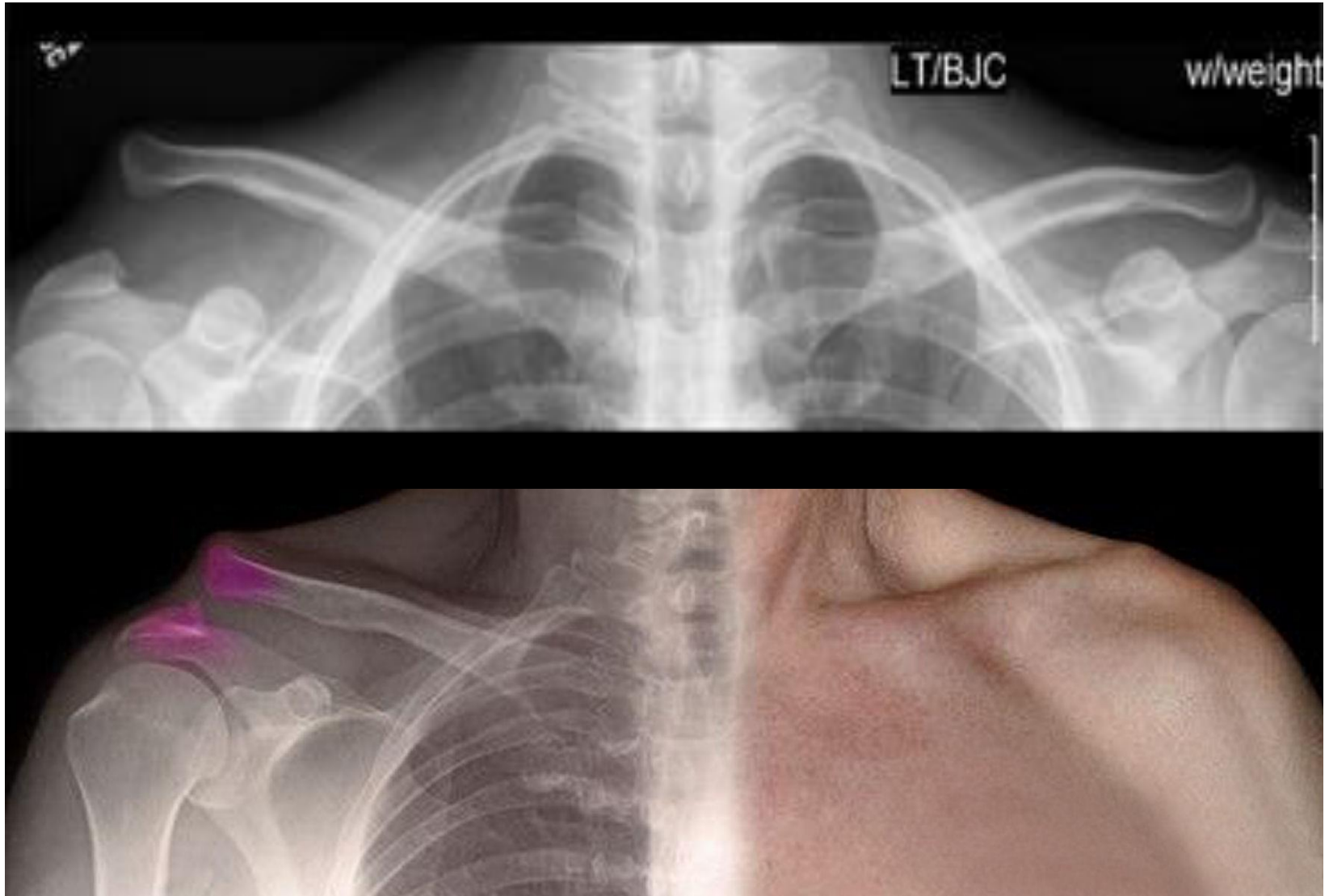


Image Sources: <http://johnpostmdsblog.blogspot.com/>, <http://www.sportsmed.org>,
<http://deepvisual.webs.com>

Sternoclavicular or SL Joint

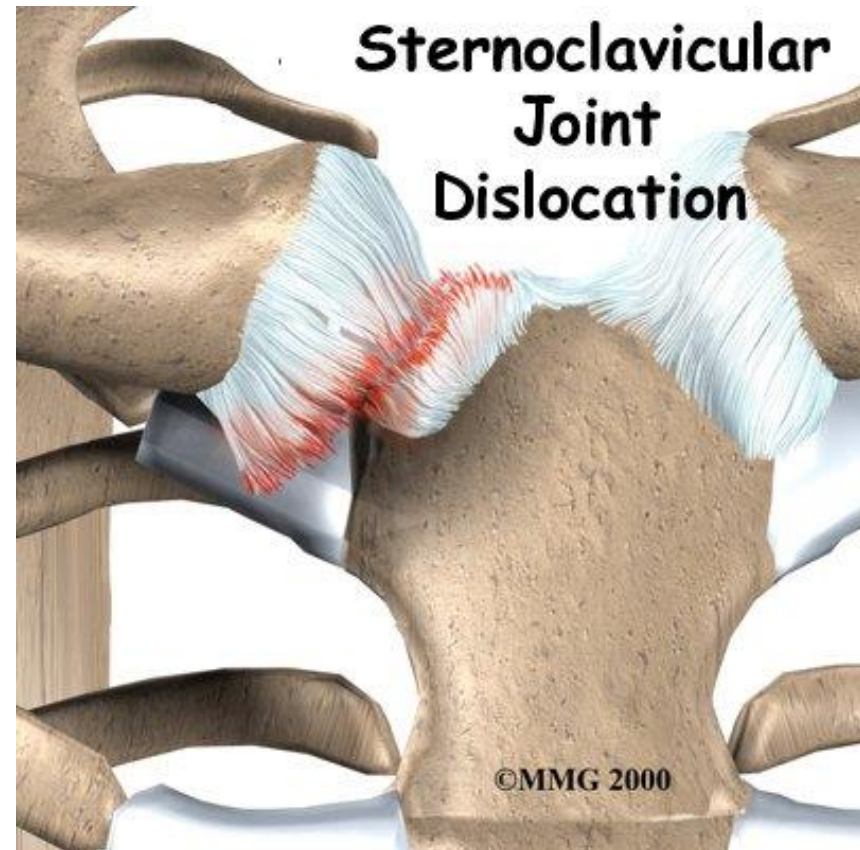
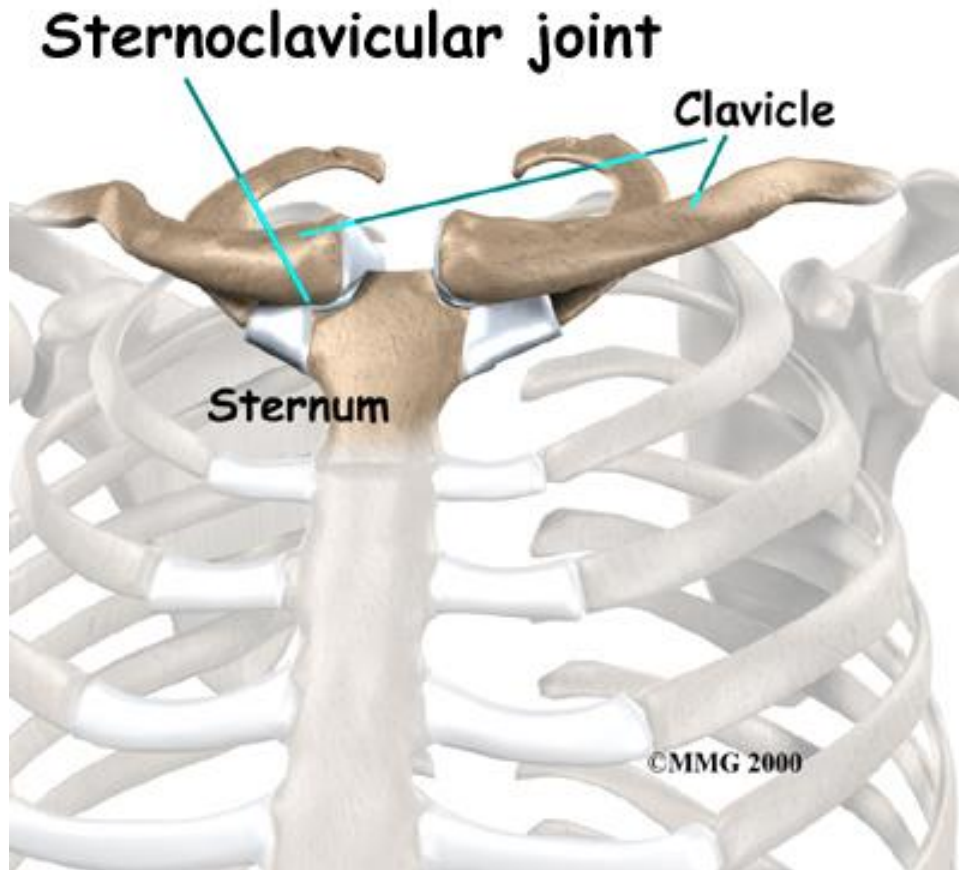


Image Sources: www.eorthopod.com, www.kneeandshouldersurgery.com

Hand

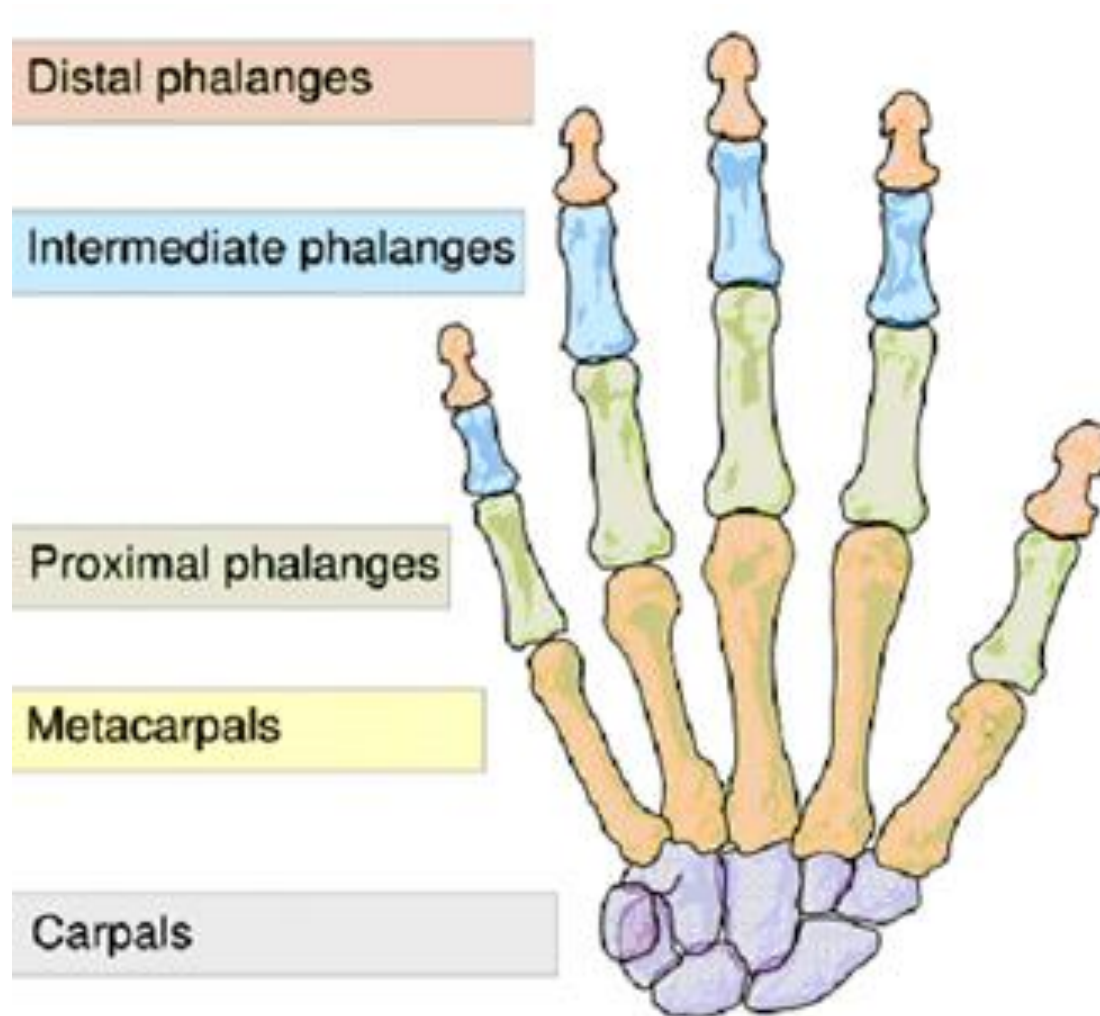


Image Source: <http://en.wikipedia.org/wiki/Hand>

Upper Extremity Exploration 3

What kind of *activity* or *force* might be involved in an *elbow dislocation*?

What *weight room activity* is most commonly involved with *fractures* of *metacarpals* and *phalanges*?

Which *group* is *most susceptible* to these fractures?

What *weight room activity* or *machine* is most commonly involved in *amputations of phalanges*?

Which *group* is *most susceptible* to amputations?

Elbow Dislocation

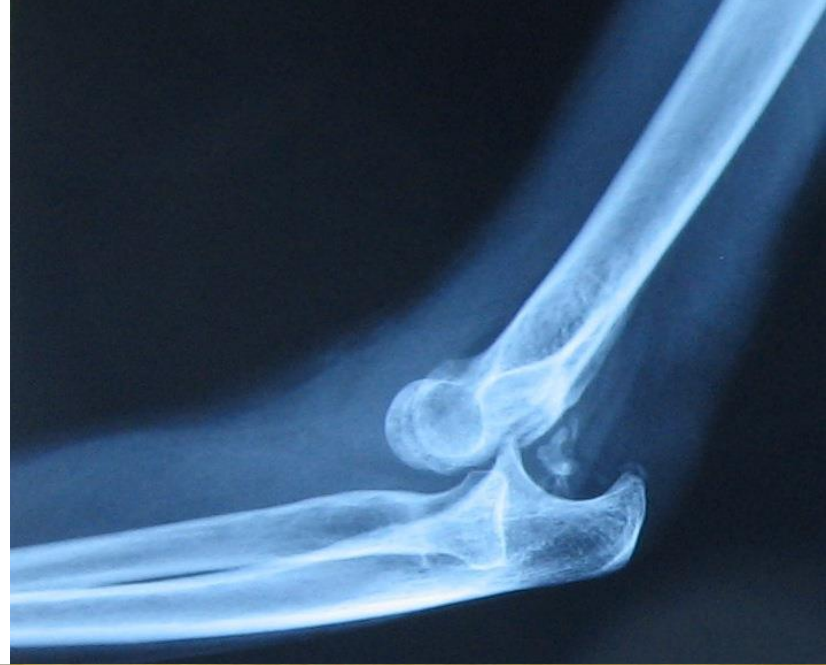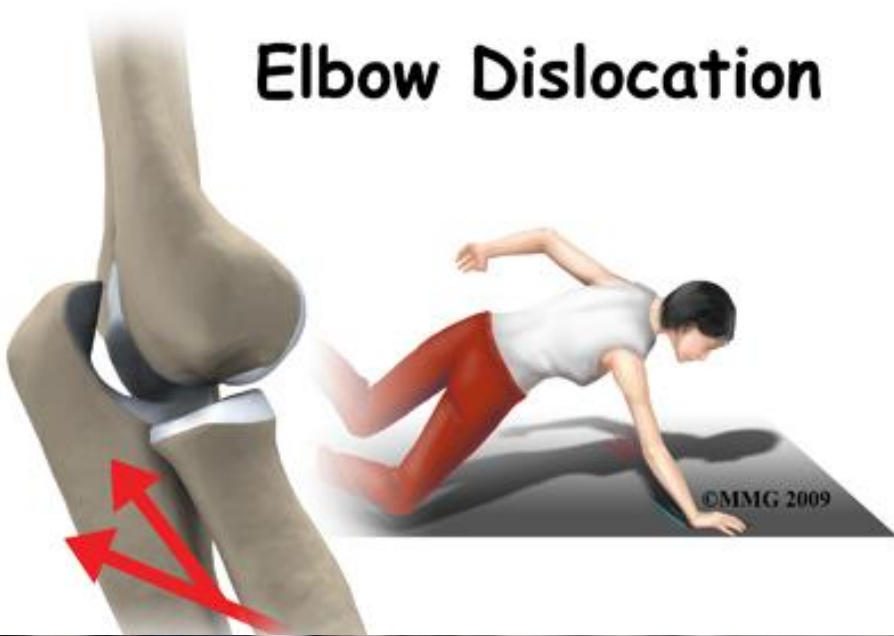


Image Sources: www.methodistorthopedics.com/, <http://boneandspine.com/>,
<http://www.sportsmd.com/>, <http://drknight-kinesiology.blogspot.com/>

Fracture of Distal, Mid or Proximal Phalange?

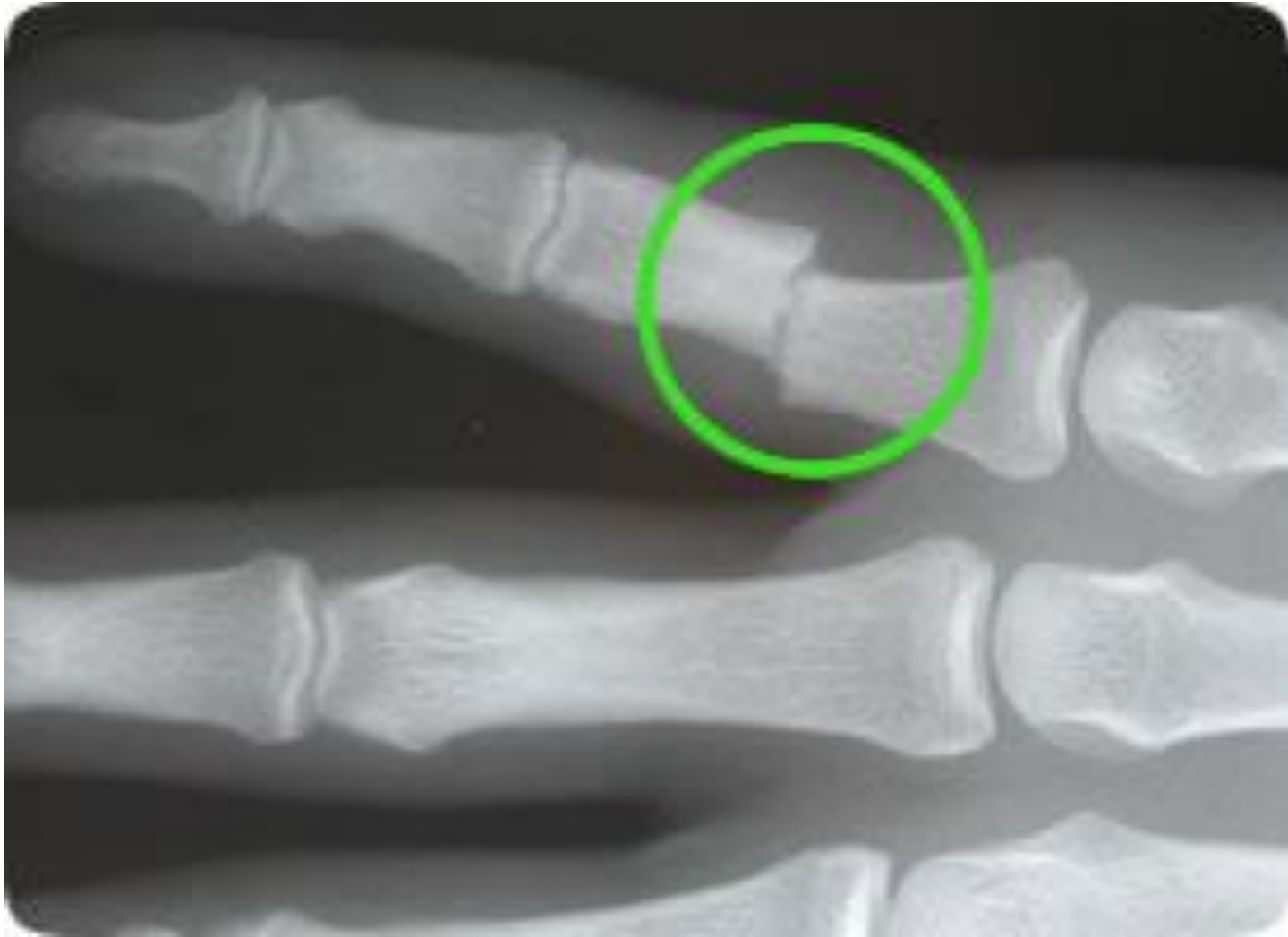

Image Source: <http://www.handsurgeonlondon.co.uk>

Dumbbells & Machine Weight Stacks!




Image Sources: www.hoopsavenue.com, ...

Women & Children are Most Susceptible: Grip Strength & Exploration!



Image Source: www.ignitumtoday.com

Upper Extremity Exploration 4

With a **red** piece of tape identify the site of a *forearm fracture*.

With a **red** piece of tape identify the site of a *wrist fracture*?

Identify the *pisiform* bone and discuss the potential for *fracture/dislocation*.

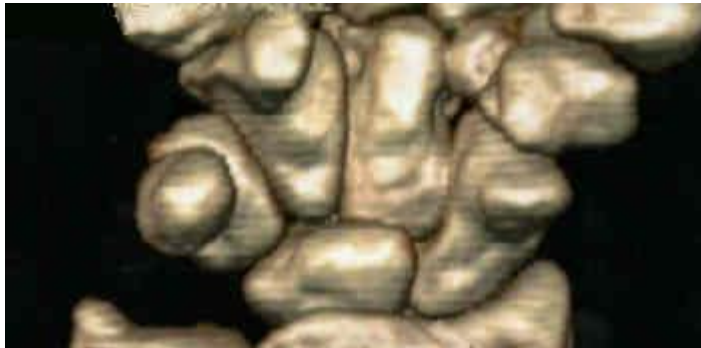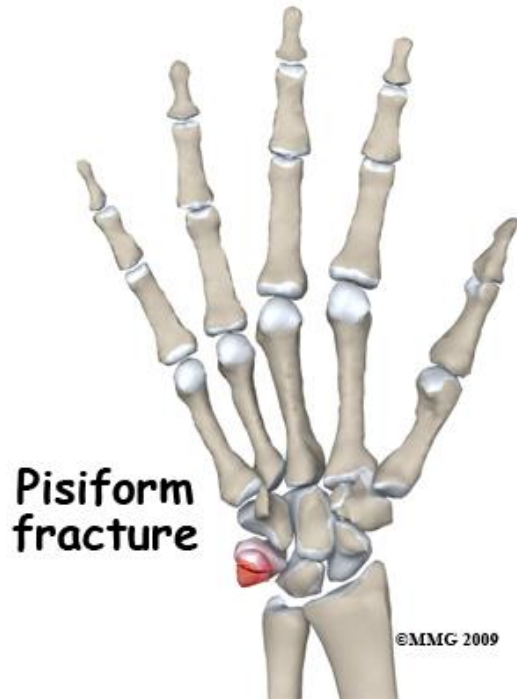
What is *carpal tunnel syndrome* & how is it treated?

How might the *casting* differ for an *elbow vs. a wrist fracture*? Why?

At this point, *formulate any questions about upper extremity joints and bones* you may have for class discussion.

Pisiform dislocations/fractures quite rare!

Journal of Orthopaedic Surgery 2010;18(3):389-90



Traumatic dislocation of the pisiform: a case report

Vitali Goriainov,¹ Grant Bayne,² David J Warwick¹

¹ Department of Trauma and Orthopaedics, Southampton University Hospitals, Southampton, United Kingdom

² Department of Trauma and Orthopaedics, Queen Alexandra Hospital, Portsmouth, United Kingdom

ABSTRACT

Isolated pisiform dislocation is rare. We present one such case in a 20-year-old man occurring after a direct injury to the wrist. After an initial delay in diagnosis and unsuccessful closed reduction, he underwent resection of the pisiform. At 12-month follow-up, he had full range of movement of the wrist and no residual pain.

Key words: *delayed diagnosis; dislocations; pisiform bone*

INTRODUCTION

Isolated pisiform dislocation is rare and hence its optimal management strategy has not been specified. We present the case of a 20-year-old man with traumatic dislocation of the pisiform, which was treated with resection.

CASE REPORT

In September 2008, a 20-year-old, right-handed man presented to the emergency department with pain in

the ulnar border of the left wrist after a fall onto the outstretched hand. He underwent immobilisation of the wrist in a plaster, but the pain persisted. He was referred to a hand specialist 2 weeks later for further assessment. The pisiform was noted to be lying across the ulnar edge of the triquetrum, with intact ulnar nerve and flexor carpi ulnaris (FCU) function noted. Radiography confirmed the diagnosis of pisiform dislocation without fractures (Fig.). In view of the absence of neurological or functional deficits, further imaging was not performed.

Two days later, closed reduction under anaesthesia was attempted but this was unsuccessful. Resection of the pisiform from the FCU tendon, with careful repair was therefore performed. The integrity of the pisiform and the FCU tendon distal to the pisiform were intact, but the pisotriquetral joint capsule was disrupted.

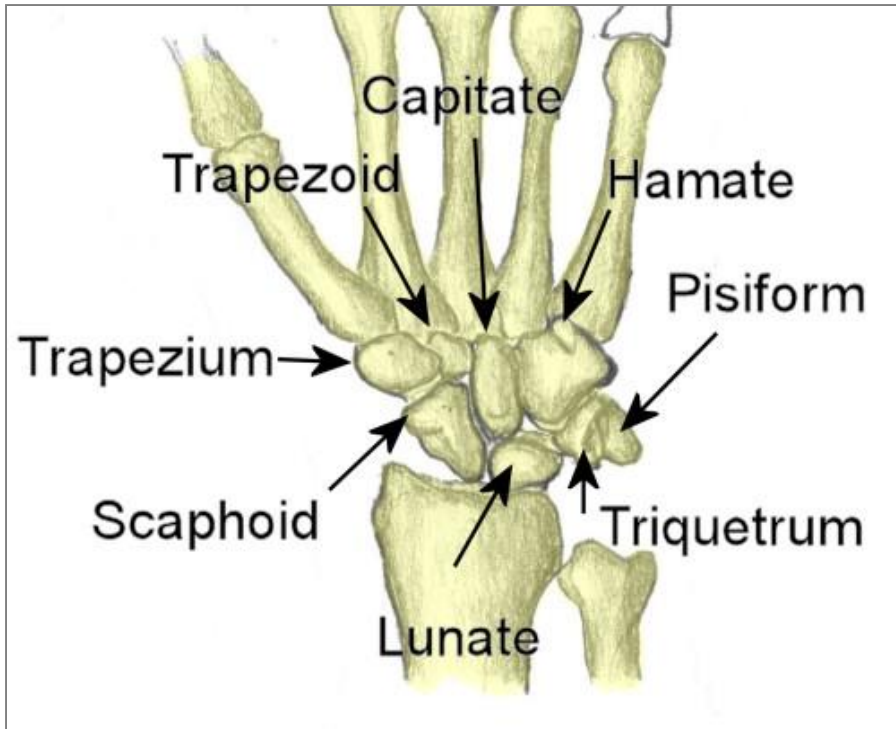
Physiotherapy was started at week 2. At 12-month follow-up, the patient had full range of movement of the wrist and no residual pain. Power grip on the injured left side was weaker than on the right (16.5 vs. 19.4 kg), but this difference was not apparent to the patient.

DISCUSSION

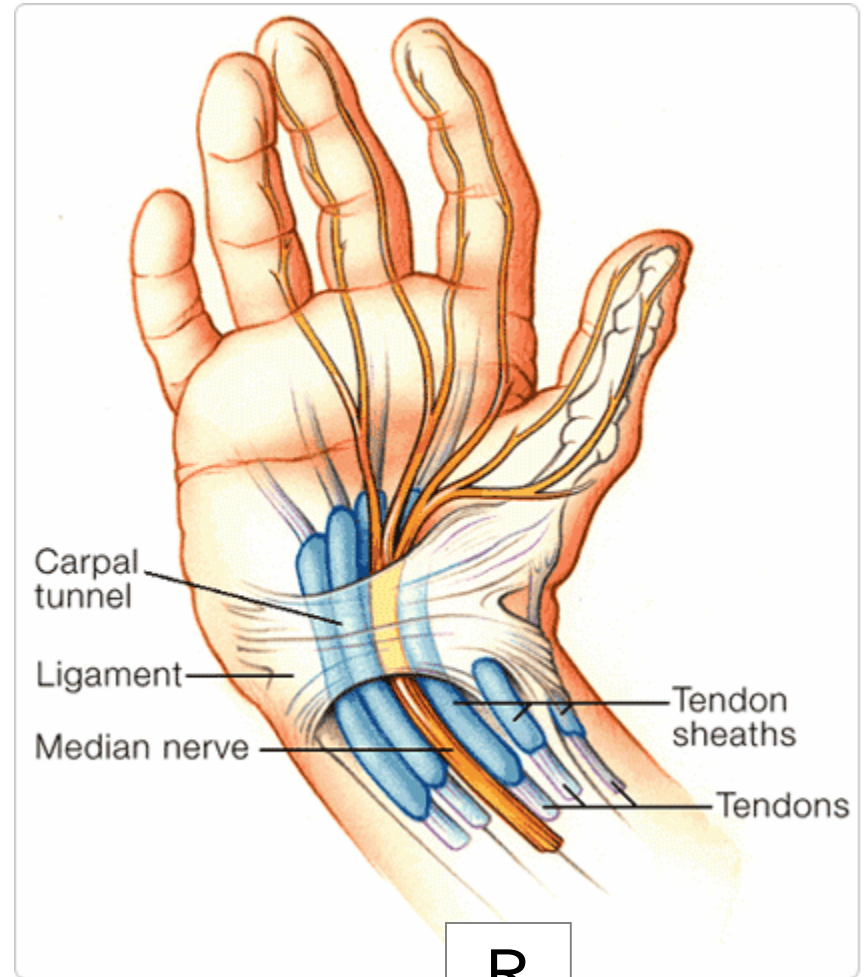
Traumatic dislocation of the wrist can result from

Address correspondence and reprint requests to: Mr Vitali Goriainov, Department of Trauma and Orthopaedics, Southampton University Hospitals, Southampton, United Kingdom. E-mail: vitaligoraiainov@hotmail.com

Carpal Tunnel



L



R

Short vs. *Long-arm* casts

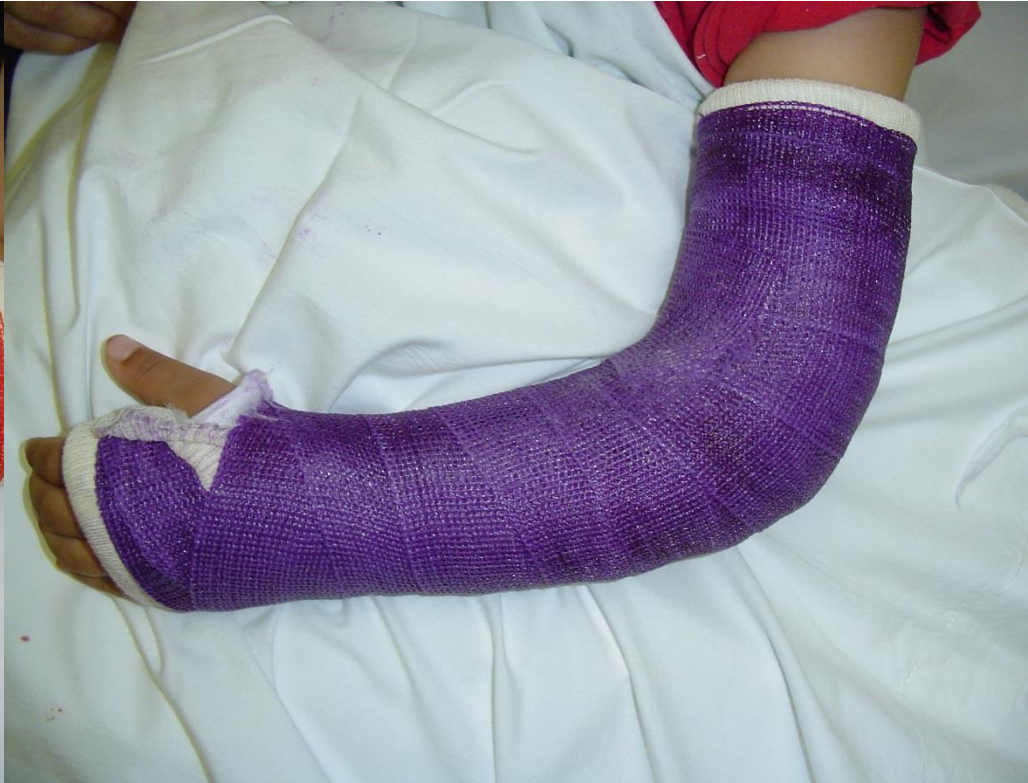
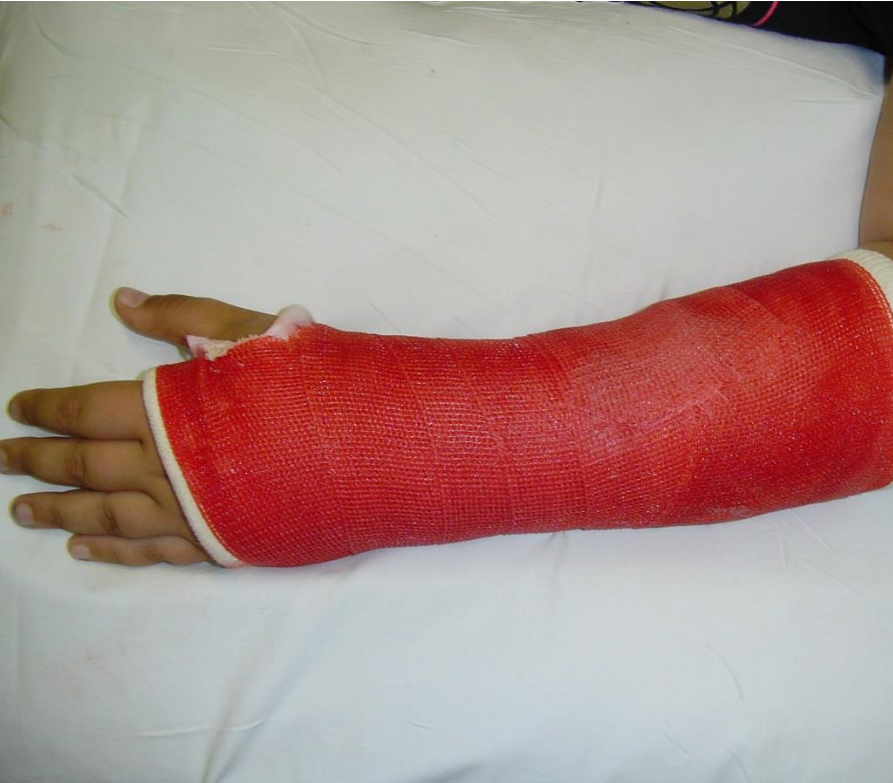
Image Source: <http://meds.queensu.ca>